

ESSKA Meniscus Consensus Project

Chairmen:



Philippe Beaufils Roland Becker

The ESSKA MENISCUS CONSENSUS INITIATIVE was initiated by the ESSKA Board after the congress in Amsterdam in 2014. It has been commissioned to two world-renowned experts in the field, Prof. Philippe Beaufils (France) and Prof. Roland Becker (Germany).

The goal of the initiative is to find a European consensus on the treatment of meniscus pathologies. Finding a consensus in such a diverse continent like Europe where medical culture and healthcare systems vary from country to country is not easy. A strict methodology has therefore been applied and numerous European experts have been involved in this process.

It is due to the merit of the two leaders of this group that we are able to come up with this document which shall be understood as guidance to ESSKA members. We thank Profs. Beaufils and Becker as well as the members of the steering, rating and peer review groups for their efforts and dedication. A special acknowledgement also goes to our staff, and particularly Mrs. Anna Hansen Rak, without whom this would not have been possible.

Milan and Luxembourg, May 2016



Matteo Denti
ESSKA Past President



Romain Seil
ESSKA President

Part One: Degenerative Meniscus Lesions

I. Introduction / Memorandum

Arthroscopic partial meniscectomy is one of the most popular orthopaedic procedures, especially in the field of degenerative meniscus lesions (DML). This introduction sets the tone for recent literature findings about different meniscal pathologies in degenerative knee diseases, encompassing both conservative and surgical management. Although there is a clear correlation between osteoarthritis and meniscal degeneration, it is sometimes difficult to establish a clear line of distinction between these two entities.

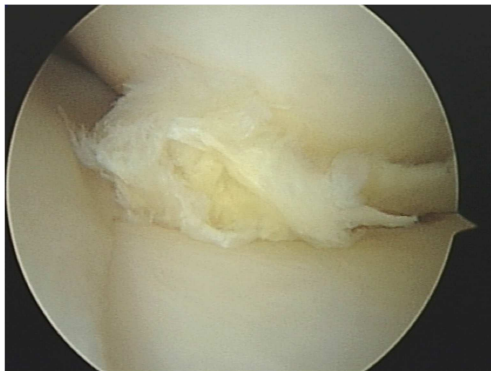


Figure 1: degenerative meniscus lesion (posterior segment of the medial meniscus; left knee)

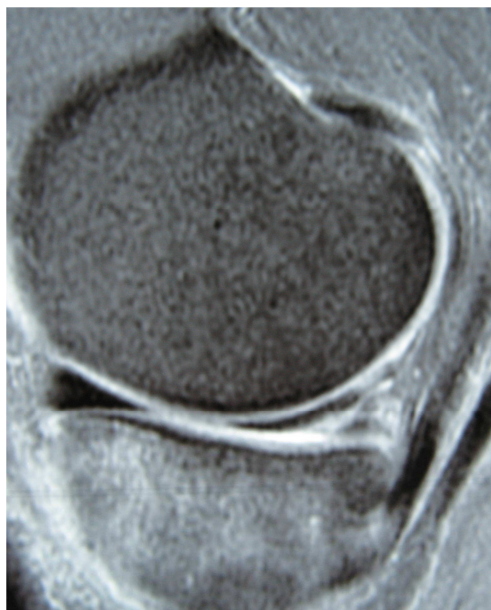


Figure 2: MRI (sagittal view T2 FS): grade3 degenerative meniscus lesion

The majority of recent RCT's state that non operative treatments of degenerative meniscus lesions (fig 1, 2) have similar results to arthroscopic surgery. These studies have been trying



to combine clinical experience, sufficient number of cases and appropriate methodology - both from the perspective of clinical research and statistical analysis - to support conclusions which may help the orthopaedic clinician to administer the best treatment. However, their analysis does not reveal a clear picture. Instead, it is one of conflict and confusion. Several editorials and letters have been published either by medical physicians (8, 10) or orthopaedic surgeons (2, 5, 7, 9) in the defence of their practice. These exchanges are confusing and have not been useful to the clinician in making treatment decisions. Therefore, there is a need for a more uniform and clear message, for as we recently wrote in a KSSTA journal editorial: “The necessity of a consensual process becomes clear, founded on the independence of the organisers and with the participation of all interested parties to produce the most exhaustive critical analysis of the literature possible. Work of this kind will permit a probable reduction in the number of arthroscopic meniscal resections in our countries in favour of abstention ... and an improved nosological definition of “meniscectomy”, rendering it pertinent and efficient” (1). We are aware that RCT’s and meta analyses, as good as they may be, have their biases and weaknesses (3, 4). “These studies, however solid they appear, should be read and interpreted with a critical scientific mind. A single study can seldom be taken as the only fact or the final truth but should contribute to the scientific debate with the ultimate objective of improving our practice”. (1) But these RCT’s exist and despite their weaknesses, they give an important message.

Bearing this in mind, we feel that the treatment of degenerative meniscus lesions should be related to both scientific evidence and clinical expertise. In order to assist surgeons in their treatment indications, ESSKA decided to build a Meniscus Consensus Project at the European level whose first part, which is discussed here, is devoted to degenerative meniscal lesions. Our goal was to propose a “framework” rather than strict guidelines. We have set up the “Formal Consensus Project” (6) (figure 3) which comprised a steering group of 13 experts. Based on the diagnostic and therapeutic workup for degenerative meniscus lesions, they proposed a series of relevant questions and their respective answers. Both were strictly in accordance with the existing literature and their own clinical expertise. A first written draft was reviewed and amended twice by a further independent panel of 20 experienced orthopaedic surgeons (rating group) (table 1) who graded each answer.

Table 1:

Grading description

- *Grade A: high scientific level*
- *Grade B: scientific presumption*
- *Grade C: low scientific level*
- *Grade D: expert opinion*

Each question of the text was rated according to discrete numerical scale running from 1 to 9 conforming to the "Formal consensus" method:

Meaning of the discontinuous numerical scale running from 1 to 9								
1	2	3	4	5	6	7	8	9
Totally inappropriate	↑ Undecided						Totally appropriate	

The final text underwent a second review process by an additional peer group comprising 50 clinicians and clinical scientists from different European countries. This complex and long process has two main advantages. It avoids any individual or organisational bias or conflict of interest and it may have a greater chance of general acceptance due to the involvement of a large number of participants and countries.

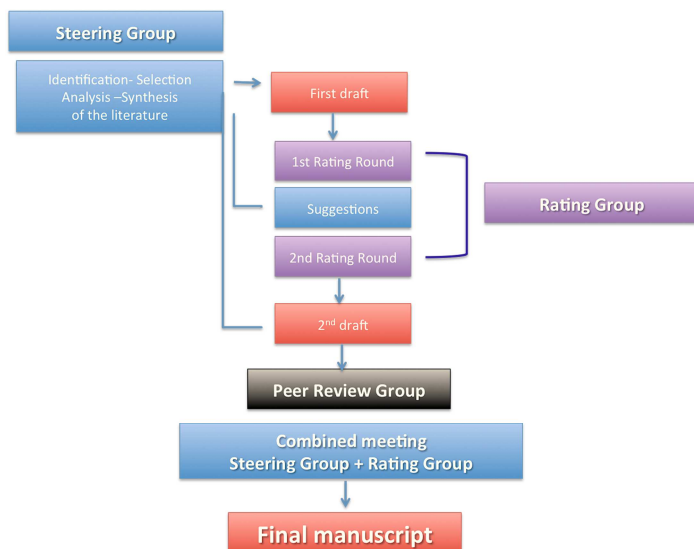


Figure 3: Formal Consensus Process

During this long process, it appeared that it was extremely difficult to accurately standardise clinical cases with degenerative meniscal pathology. This perfectly reflected the large



diversity of clinical presentations in our daily practice. Just like the large amount of individual anatomical variations, the orthopaedic clinician needs to face each individual patient with his or her unique medical history, individual physiology, gender, activity level, weight and a number of other variables that do not fit into a single statistical picture. This “consensus investigation” has attempted to shine some light onto these mundane but extremely important clinical entities. In addition, the recommendations are presented free from economic constraints.

We hope the following recommendations will take into account these messages, avoid any conflicting or political statements, and provide a well balanced treatment algorithm with a place for both non operative and arthroscopic treatment in the orthopaedic armamentarium. Our findings will hopefully assist every orthopaedic clinician in their decision making when confronted with patients with degenerative meniscal pathology in a symptomatic knee. Furthermore, if the cases were to be documented prospectively they could be used to refine the guidelines once a critical mass of data has been obtained. In the future we believe there will be no difference between the individual clinician’s own knowledge base and the so called “scientific criteria”, whereas at present this is not the case.

Philippe Beaufils, Roland Becker, Rene Verdonk

Acknowledgements:

We would like to deeply thank:

The members of the Steering Group who did a huge work: S. Kopf (Germany), M. Ollivier (France), M. Englund (Sweden), R. Verdonk (Belgium), N. Darabos (Croatia), A. Gökeler (The Netherlands), M. Hirschmann (Switzerland), C. Hulet (France), T. Järvelä (Finland), H. Mayr (Germany), P. Ntangiopoulos (Greece), H. Pereira (Portugal), N. Rotigliano (Italy)

The members of the Rating Group: H. Aagaard (Denmark), B. Barenus (Sweden), T. De Coninck (Belgium), D. Dejour (France), M. Denti (Italy), J. Espregueira-Mendes (Portugal), C. Fink (Austria), P. Gelber (Spain), A. Goergoulis (Greece), J. Höher (Germany), M. Karahan (Turkey), J. Menetrey (Switzerland), JC. Monllau (Spain), R. Müller-Rath (Germany), D. Popescu (Spain), N. Pujol (France), P. Randelli (Italy), R. Seil (Luxemburg), B. Sonnery-Cottet (France), A. van Haver (Belgium), T. van Tienen (The Netherlands), P. Verdonk (Belgium), A. Williams (UK), S. Zaffagnini (Italy)

The 50 members of the Peer Review group among 21 European countries.

Mrs Anna Hansen Rak from ESSKA Office without whom nothing would have been possible.



Neil Thomas (UK) who reviewed the manuscript and helped us to polish the text in a native English language.

References:

1. Beaufils P, Becker R, Verdonk R, Aagaard H, Karlsson J. Focusing on results after meniscus surgery. *Knee Surg Sports Traumatol Arthrosc.* 2015;23(1):3-7.
2. Bollen S R. Is arthroscopy of the knee completely useless? *Bone Joint J* 2015, 97 B, 1591-2
3. Chess L, Gagnier J. Risk of Bias of controlled trials published in orthopaedic journals. *BMC Med Res Methodol* 2013 13:76–85
4. Clavien PA, Puhan MA. Biased reporting in surgery. *Br J Surg* 2014; 101 (6):591-2
5. El Attrache N, Lattermann C, Hannon M, Cole B. New England Journal of Medicine Article evaluating the usefulness of meniscectomy is flawed. *Arthroscopy* 2014 30(5):542–543
6. Haute Autorité de Santé http://www.has-sante.fr/portail/jcms/c_272505/en/-formal-consensus-method; consulted November 2014
7. Lubowitz JH, Provencher MT, Rossi MJ. Could the New England Journal of Medicine be biased against arthroscopic knee surgery? *Arthroscopy* 2014 30(6):654–5.
8. Lohmander LS, Thorlund JB, Roos EM. Routine knee arthroscopic surgery for the painful knee in middle-aged and old patients-time to abandon ship. *Acta Orthop.* 2016 ;87(1):2-4.
9. Rossi MJ, D'Agostino RB Jr, Provencher MT, Lubowitz JH. Could the New England Journal of Medicine be biased against arthroscopic knee surgery? *Arthroscopy* 2014 30(5):536–537
10. Thorlund JB, Juhl CB, Roos EM, Lohmander LS. Arthroscopic surgery for degenerative knee: systematic review and meta-analysis of benefits and harms. *Br J Sports Med.* 2015; 49(19):1229-35

II. Background

Q1) What is a degenerative meniscus lesion?

Steering group answer:

A degenerative meniscus lesion is a slowly developing lesion, typically involving a horizontal cleavage of the meniscus in a middle-aged or older person. Such meniscus lesions are frequent in the general population and are often incidental findings on knee MRI. The pathogenesis is not fully understood. There is often no clear history of an acute knee injury.

Grade B

Literature review:

Meniscus tears can be categorized crudely based on their principal cause: knee trauma or degeneration. *Traumatic* meniscus tears are associated with a history of acute knee trauma and an onset of symptoms that is typically closely related to the traumatic incident. However degenerative meniscus lesions have a slower, complex and still poorly understood pathogenesis, as well as being more frequently asymptomatic. Increasing evidence supports the concept that they occur in meniscus tissue already ongoing degenerative change (1-4). The most typical morphological configurations of these tears are horizontal cleavages and/or flap tears with a horizontal component most commonly involving the medial meniscus body and/or the posterior horn (5, 6).

The only longitudinal (natural history) study with repeat MR imaging capturing the development of meniscus lesions in middle-aged persons reported only 1 of 43 “incident” meniscus tears was associated with acute knee trauma (7). Instead it was a slowly developing process (over several years) potentially involving progressive mucoid degeneration and weakening of the meniscus ultrastructure (figure 1).

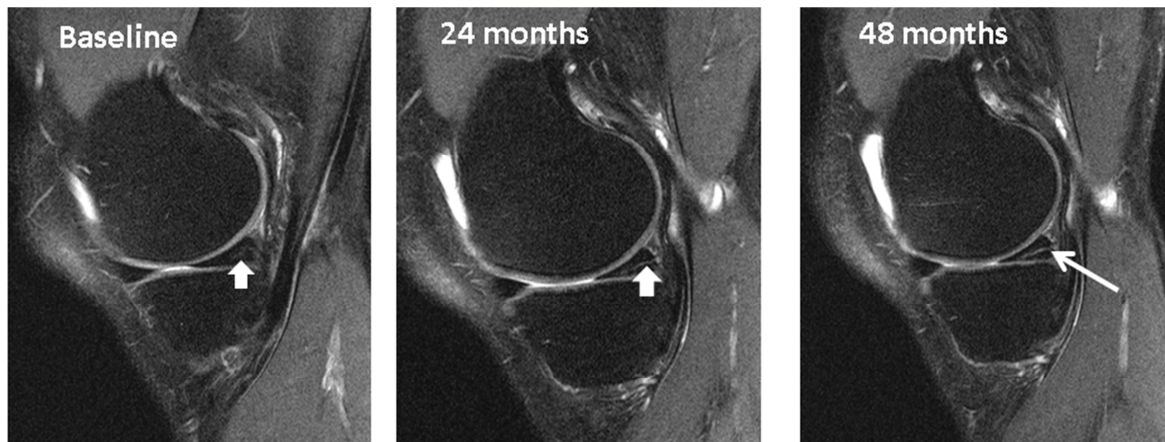

Figure 1 The development of intrameniscal signal into a horizontal cleavage lesion in the posterior horn of a medial meniscus over the period of 4 years captured on repeat 3-Tesla knee MRI.

The presence of an intra-meniscal signal of linear character on MR images can be considered a risk factor for a degenerative meniscus lesion (3, 4, 7). However in some susceptible individuals a degenerative meniscus lesion can be elicited by minor knee trauma or chronic high repetitive knee loading (8). Knee malalignment, obesity, and occupational hazards could result in such unfavourable chronic overloading. Such overloading, coupled with degenerative meniscus matrix changes possibly related to an early stage of osteoarthritis, could lead to meniscal fatigue, rupture, and extrusion (9-11). Once the meniscus loses a part of its critical function in the knee joint, the increased biomechanical loading patterns on joint cartilage may result in accelerated cartilage loss(12, 13), bone alterations including trabecular bone changes (14-16), increased bone mineral density (17), development of subchondral bone marrow lesions (18), and increasing malalignment – the vicious cycle of knee osteoarthritis is in motion.

In support, risk factors reported to be associated with development of degenerative meniscus lesions are malalignment of the knee (the more loaded compartment) and the presence of signs of hand osteoarthritis suggesting systemic or potentially a common environmental factor (9). Further, in cross-sectional studies floor layers have been found to have a higher prevalence of lesions than graphic designers suggesting occupational load may contribute although limited causal inference can be drawn due to the cross-sectional nature of the data (10).

So, in brief degenerative meniscus lesions have a more complex multifactorial pathogenesis than traumatic meniscus tears. Much uncertainty about the degeneration itself remains in the



former The further osteoarthritic process in the ‘meniscal pathway’ to knee osteoarthritis may be the pathological response of joint tissues to the abnormal biomechanical stress in these individuals due to partial loss of meniscus function (8).

Q2) Which MRI criteria characterize a degenerative meniscus lesion?

Steering group answer:

A degenerative meniscus lesion is usually characterized by linear intrameniscal MRI signal (including a component with horizontal pattern) often communicating with the inferior meniscal surface on at least two image slices. A more complex tear pattern in multiple configurations may also occur. The most common location of a degenerative meniscus lesion is the body and (or) posterior horn of the medial meniscus.

Grade B

Literature review:

In the clinical setting knee MRI is rarely indicated for the degenerative knee. As a degenerative meniscus lesion is poorly associated with symptoms, a ‘diagnosis’ of degenerative meniscus tear should be avoided. Instead it should be considered a feature indicative of early stage knee osteoarthritis or an ageing knee, and the patient be treated accordingly.

A degenerative meniscus lesion can however (typically for research purposes), be classified on the basis of the morphological appearance on knee MRI using a suitable protocol:

An increased meniscal signal should be indicative of a meniscus tear when it communicates with the inferior, superior, or free edge of the meniscal surface (or more than one of those) on at least two consecutive MR images (or for a radial tear, if it is visible on both the coronal and sagittal images) (19-22). Meniscus tears can in general be categorized as follows: *i)horizontal*, defined as a tear parallel to the tibial plateau separating the meniscus into upper and lower parts; *ii)oblique (parrot-beak)*, defined as a tear oblique to the circumferentially oriented collagen fibres; *iii)longitudinal*, defined as a vertical tear perpendicular to the tibial plateau and parallel to the orientation of the circumferential fibres; *iv)radial*, defined as a vertical tear that begin in the central free margin and is perpendicular both to the tibial plateau and to the circumferential fibre orientation; *v)complex*, defined as multiple tears in more than one configuration; and *vi)root*, defined as a tear in the posterior or anterior central

meniscal attachment (23). The absence of meniscal tissue owing to complete maceration, destruction, or surgical resection can be classified as *vii)meniscal destruction*.

Typical degenerative meniscus lesions are the horizontal cleavage lesion, the flap tear, or complex tear which may involve a flap typically located in the posterior horn (5, 21). It is likely that radial meniscus tears may also have a degenerative origin although their pathogenesis is more speculative. It is important to note that a radial tear or a root tear that extends all the way to the capsule has severe consequences for meniscus function as it transects all the way through the circumferentially oriented collagen fibres. This is the main orientation of the fibres and is critical in generating the hoop tension which prevents meniscus extrusion (radial displacement).

Q3) What is the prevalence of degenerative meniscus lesions?

Steering group answer:

The prevalence of meniscus lesions (on the knee level) in the general population (intrameniscal signal extending to surface according to the two-slice touch rule (19, 20)):

Age 50-59 years ≈25%

Age 60-69 years ≈35%

Age 70-79 years ≈45%

Patients with knee osteoarthritis ≈ 75-95%

Please note that the estimates above do not include meniscus destruction/maceration, i.e., absence of normal meniscus tissue which is also a frequent finding particularly in elderly women (please see graph below).

Grade B

Literature review:

It is imperative to understand that degenerative meniscus lesions are extremely common – the prevalence of degenerative meniscus lesions in the *general* population increases with increasing age, ranging from 16% in knees of 50 to 59 year-old women to over 50% in the knees of men aged 70 to 90 years (figure 2)(5). These data are derived from a *randomly* selected sample from the *general* population, i.e., the persons were *not* selected on the basis of

having knee joint symptoms (or *not* having symptoms). In addition, some 10% of right knees in the Framingham study had partial destruction/maceration, i.e., absence of normal meniscal tissue (of all without prior knee surgery). This is not classified as a meniscus tear but is a finding typically associated with other structural changes or evidence of osteoarthritis. It is a likely part of osteoarthritic degradation leading to maceration of the meniscus and its destruction. In knees with osteoarthritis, a prevalence of meniscus tear of over 90% has been reported in knees of patients with symptomatic knee osteoarthritis (24-26).

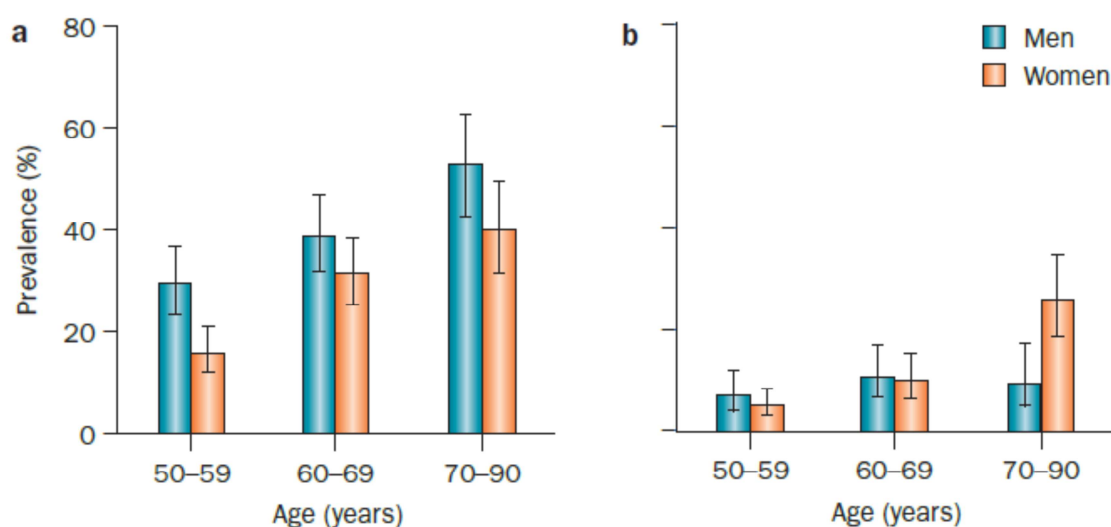


Figure 2. The prevalence of meniscus lesions and destruction in a randomly recruited population-based sample. a) Meniscus tear and b) meniscus destruction (not classified as a tear) in the right knee of men (n=426) and women (n=565) aged 50 to 90 from Framingham, Massachusetts, USA. The diagnosis was based on MRI. Participants were not selected on the basis of knee or other joint problems. Error bars show the 95% CI (reprinted with permission from New Engl J Med).

These epidemiologic data are important in two aspects: First, they demonstrate the remarkably high prevalence of meniscus lesions in the general population – a prevalence so high it may even be considered part of normal ageing. Second, most of these meniscus lesions do not directly cause knee symptoms as over 60% of tears were seen in study participants completely free of knee pain, aching or stiffness (5). It is important to point out that this study was population-based and study subjects were randomly sampled, i.e., *not* sampled on the basis of the presence or absence of any knee joint symptoms. Thus, degenerative meniscus lesions may often be misinterpreted to be the cause of knee pain or knee joint discomfort as they are the one pathology typically found on knee MR images or

incidentally at arthroscopy. Just because a meniscus lesion is identified in a patient reporting knee symptoms does not necessarily imply that it is a “symptomatic meniscus tear”. Pain may originate from other structures or processes that may, or may not, be visible on MRI (please see below).

Q4) Do degenerative meniscus lesions cause knee symptoms?

Steering group answer:

There is very limited evidence that pain in the degenerative knee is directly attributable to a degenerative meniscus lesion even if the lesion is considered to be unstable. Great caution must be taken before arriving at the conclusion that the degenerative meniscus lesion is the direct cause to the patient’s knee symptoms.

Grade B

Literature review:

The association between degenerative meniscus lesions and knee symptoms is challenging to disentangle. This is true in knees with clear evidence of radiographic osteoarthritis as well as in knees with no or little other evidence of osteoarthritis (5, 26, 27). Already in 1974 Noble and Hamblen reported from a series of necropsy studies that “*The horizontal cleavage lesion probably exists much more commonly than symptoms arising from it. Therefore, other factors must be involved in the production of symptoms*” (2).

In the Framingham Community Study the majority (61%) of persons (age 50-90 years) with a meniscus lesion (screened with knee MRI) did not report any knee pain aching or stiffness. Virtually all of the tears were very typical horizontal cleavages, complex, and or even oblique/flap tears, i.e., typical degenerative lesions. No distinction was noted as to whether the tear was classified as large or involving the peripheral one third or a flap. Importantly, just because in the remaining 39% of study subjects with meniscus lesion found on MRI reported some pain, aching or stiffness in their knee does not necessarily mean the meniscus lesion was the direct cause. Most of these community-based persons with knee symptoms also had radiographic evidence of osteoarthritis and other features that may explain symptoms such as the presence of subchondral bone marrow lesions (18, 28). Also, Zanetti and co-workers reported the presence of meniscus lesions on MRI in the contra-lateral *asymptomatic* knee in 63% of patients (mean age 42 years, range 18-73) scheduled for arthroscopy due to a meniscus tear.

Importantly, there is mounting evidence that the link between the actual degenerative meniscus lesion and symptoms is often spurious, i.e., the meniscus gets wrongly blamed as the cause when it is other processes that are directly involved in the patients symptoms (2, 26, 29, 30). For example, the pain may be the result of compromised meniscal function of a torn and extruded meniscus leading to increased stress on joint cartilage and subchondral bone, which may result in subchondral bone marrow lesions (18). Bone marrow lesions have been found to be associated with knee pain and fluctuations in knee pain (28, 31).

Meniscus tears are also reported to be associated with synovitis which may be a source of pain(32). Recently, increased vascular penetration and nerve growth have also been reported of the menisci obtained from osteoarthritic knees (33).

A parameniscal cyst may occasionally develop and is virtually always associated with degenerative horizontal cleavage lesion (34, 35). These cysts likely develop due to leakage of synovial fluid and may be associated with joint line discomfort (36).

The exact source of knee pain is naturally very complex to disentangle and the absence of evidence does not rule out that in individual patients, a degenerative meniscus lesion itself may cause symptoms. However, considering the high frequency of these lesions in the general population and firm evidence from the Finnish placebo meniscus resection trial, careful consideration must be done before arriving at that conclusion.

Although a cross-sectional study indicated meniscus extrusion – a feature often co-existing with a degenerative meniscus lesion – to be more frequent in painful knees than the contralateral non-painful knee of similar radiographic osteoarthritis stage, it is still largely unknown but plausible that meniscus extrusion may be directly associated with pain due to, for example, stretching/irritation of the synovial capsule (37).

Health care professionals seeing patients with knee pain need to be aware of the fact that a meniscuslesion may be asymptomatic *per se* in a patient with knee pain. Just because there is a degenerative meniscus lesion, visible on knee MRI or at arthroscopy, it does not necessarily imply the torn meniscal tissue is actually painful, so that surgical resection will resolve the patient's pain or aid the patient in the long term (38-40). Catching sensations may be due to other issues in the knee such as cartilage defects or just simply sudden painful sensations misinterpreted as 'mechanical' of nature.

There is very limited evidence of the accuracy of clinical tests to reliably identify unstable degenerative meniscus lesions. Most of the evaluating studies, e.g., of McMurray's or Apley's test typically include patients with knee trauma, mixed study samples and (or) have a cross-sectional design (41-44). A common fundamental flaw in the study of clinical tests for meniscus tears is the often underlying assumption that all meniscus tears identified are the cause of knee symptoms. Further challenges are the unspecific nature of clicking and popping sensations as well as the many other features/processes that may be involved in the production of joint line tenderness and pain in the degenerate knee (28, 31, 45). Therefore, the true answer as to the clinical usefulness of meniscal tests in the degenerate knee can only be determined by its integration into examiner-blinded sham meniscus surgery-controlled randomized clinical trials similar to the Finnish trial by Sihvonen et al (29, 46).

Q5) What are the consequences by a degenerative meniscus lesion in the knee?

Steering group answer:

Loss of meniscus function may negatively affect the knee in the long term. Therefore, in many people the degenerative meniscus lesion (which may impair the force transmission and load distribution capabilities of the meniscus) is a feature indicative of a knee joint with (or at increased risk of) developing osteoarthritis.

Grade B

Literature review:

The biomechanical effect of loss of meniscus function by meniscus resection is well documented in multiple biomechanical studies (47-52). However, a torn meniscus may also lead to loss of meniscus function. This is true also for a degenerative meniscus lesion. People with a degenerative meniscus lesion are at highly increased risk of developing radiographic tibiofemoral osteoarthritis (53) probably due to the potential partial loss of meniscus function primarily in load distribution. Further, the cartilage loss has been reported predominantly in the vicinity of where the meniscus lesion is located suggesting a cause and effect relationship between meniscus lesions and the structural progression of osteoarthritis (54).

The relationship between a degenerative meniscus lesion (and knee arthroscopy) and osteonecrosis of the knee is more speculative. (55, 56) There is very limited knowledge on the cause and effect relationship, but considering how frequent degenerative meniscus lesions are

in the general population, the lesion *per se* is unlikely to be an important factor associated with this relatively rare condition.

Another critical aspect of the meniscus, in addition to its morphologic integrity, is its positioning within the knee joint. Meniscus lesions, for example, are often accompanied by a varying degree of meniscus extrusion, i.e., radial displacement of the meniscus outside the joint margin (57). Several investigators have reported more frequent meniscus extrusion of the meniscus body in the osteoarthritic knee (58-60). Also, meniscus extrusion and low coverage of the tibial surface of meniscus have been reported to be a potent risk factor for cartilage loss (13, 61). Furthermore, medial meniscus body extrusion is a strong risk factor for the development of bone marrow lesions (18). Extensive meniscus extrusion or maceration is also reported to be a contributing factor to the joint space narrowing seen on conventional tibiofemoral radiographs, i.e., joint space narrowing may not all be explained by loss of joint cartilage (62-65). However, there are also studies suggesting that tibiofemoral joint space doesn't necessarily change immediately, at least after partial meniscectomy (66, 67).

Q6) Are degenerative meniscus lesions a cause or consequence of knee osteoarthritis?

Steering group answer:

The answer to this question is still unclear. However, one causal pathway does not necessarily exclude the other, i.e., one phenotype of knee osteoarthritis may start with meniscus degradation and degenerative lesion leading to loss of meniscus function and osteoarthritis development. In turn, osteoarthritis and its general degradation of the knee joint, involving multiple structures, may also cause degenerative meniscus lesions and extrusion that further accelerate structural progression of the disease.

Grade B

Literature review:

Knee osteoarthritis is often a result of increased biomechanical loading in susceptible individuals and the pathological response of joint tissues to this abnormal biomechanical stress (8). Knee malalignment, obesity and occupational hazards might result in chronic overloading, which, in combination with degenerative meniscal matrix changes (possibly related to early-stage osteoarthritis), could lead to meniscal fatigue, rupture and extrusion (9-

11). This chain of events could also be triggered by a knee trauma where meniscus function is lost in a previously healthy knee. Once the meniscus loses its critical function in the knee joint, the increased biomechanical loading patterns on joint cartilage might result in cartilage loss (12, 13), bone alterations including trabecular bone changes (16), increased bone mineral density (17), development of subchondral bone marrow lesions (18), and increasing malalignment; the vicious cycle of knee OA is set in motion (figure 3). The biomechanical effect of loss of meniscus function is well documented in multiple biomechanical studies (47, 49, 51, 68-70).

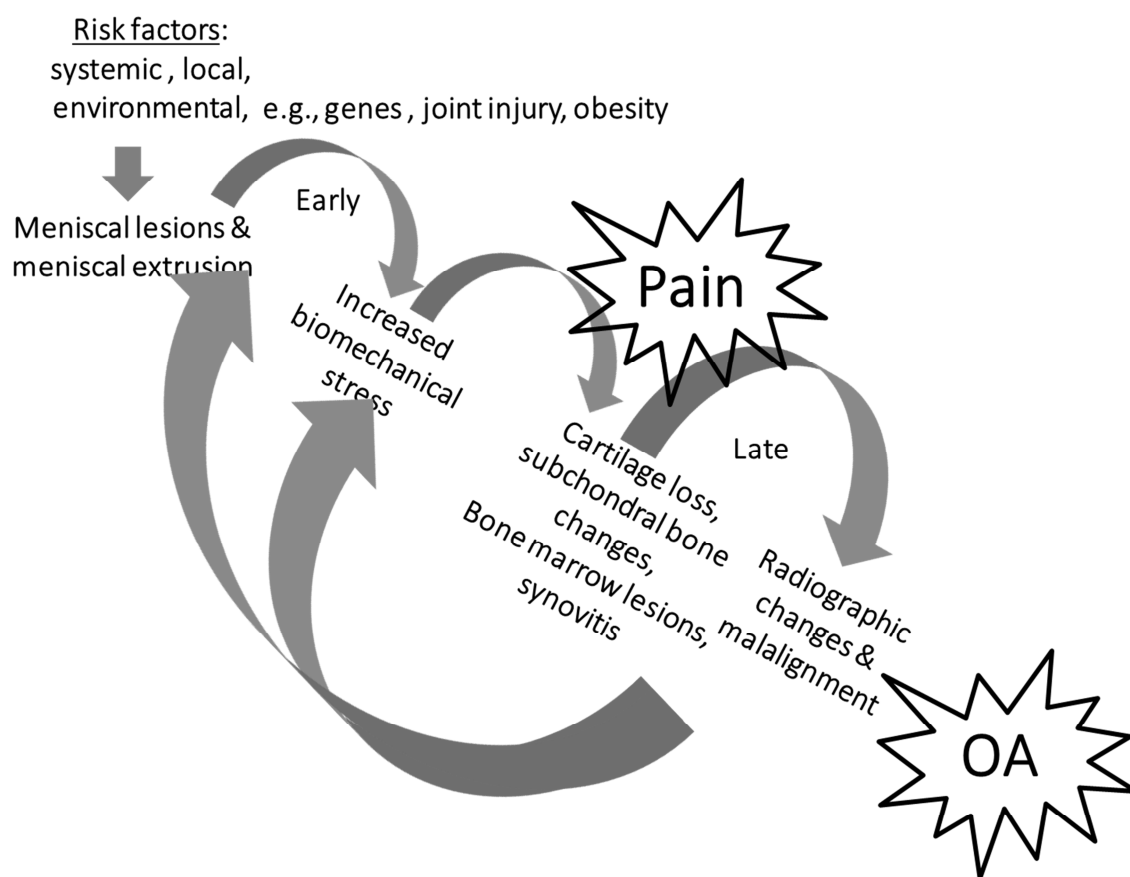


Figure 3. Meniscal pathway to knee osteoarthritis (OA).

Q7) What is the role of kneeradiographs in the assessment of middle-aged or older patients with a painful knee?

Steering group answer:

Knee radiography should be used as a first line imaging tool to support a diagnosis of osteoarthritis or to detect certain rarer pathologies of the knee. Therefore, at least

anteroposterior weight-bearing semi-flexed knee radiography including a lateral view should be included in the work up of the middle-aged or older patient with knee pain.

Grade B

Literature review:

The most typical features of osteoarthritis on radiography are osteophytes and joint space narrowing, which support the clinical diagnosis of osteoarthritis. It is important, however, to remember that the association between radiographic severity of osteoarthritis and knee joint symptoms is quite low (71). To define sensitivity and specificity of knee radiography to detect osteoarthritis in a clinical setting is challenging due to our current inability to be able to accurately define the ‘threshold’ of when to ‘call out’ the degenerate knee as having osteoarthritis. This is mainly due to the slow progressive nature of osteoarthritis, the involvement of multiple structural features/processes, and the poor correlation between structural pathology and the often fluctuating nature of patient-reported symptoms (71). However, as general rule of thumb, the sensitivity with radiography is considered to be moderate while the specificity is considered to be high. This means that with knee radiography: 1) we capture a fair amount of all patients with knee osteoarthritis, but far from all of those with the true disease (in particular not early stage knee osteoarthritis), and 2) knee radiography is unlikely to produce false positive findings of osteoarthritis. A normal semi-flexed weight bearing knee radiograph should *not* rule out the clinical diagnosis of early stage (pre-radiographic) osteoarthritis. Further, for the *general practitioner* (i.e. not in a specialized orthopaedic setting), knee radiography is often not needed in the primary work up of the middle-aged or older patient with knee joint symptoms.

Q8) What is the role of knee MRI in the assessment of a middle-aged or older patient with a painful knee?

Steering group answer:

Knee MRI is typically not indicated in the first line work up of the middle-aged or older patients with knee joint symptoms. However, knee MRI may be indicated in selected patients with refractory symptoms or in the presence of ‘warning flags’ or localized symptoms indicating ararer disease that needs to be ruled out, e.g., osteonecrosis. Hence, if a surgical indication is considered, based on history, symptoms, clinical exam and knee

radiography, knee MRI may be useful to identify structural knee pathologies that may (or may not) be relevant for the symptoms.

Grade B

Literature review:

MRI captures an incredible amount of tissue change, but today there is very limited knowledge of how to differentiate normal ageing processes from pathological ones and where does e.g., osteoarthritic processes fit in? (72). Importantly, in the clinical setting knee MRI is rarely indicated in the workup of middle-aged or older patient with knee pain. It should be used primarily conservatively to save resources but also to avoid the risk of incidental findings, i.e., findings with no or very little clinical relevance that generate unnecessary concerns (over diagnosis) or unnecessary treatments. Such incidental findings on MRI are to be considered a rule rather than an exception in the middle-aged or older patient (5, 72). Thus, the treatment decision (e.g., surgery or no surgery) should primarily be made on the patient's history, patient's symptoms and findings from clinical examination. Knee MRI may be indicated (after x-rays) in selected cases with refractory symptoms or in the presence of 'warning flags' or symptoms indicating rarer disease that needs to be ruled out, e.g., osteonecrosis.

In research, however, knee MRI is a useful tool to gain new knowledge of the aetiology and progression of knee osteoarthritis which is a disease involving the whole joint including the menisci. There are also *suggested* criteria to define knee osteoarthritis on MRI for *research* purposes (73). According to the report, a definition of tibiofemoral osteoarthritis on MRI would be:

The presence of *both* group A features or *one* 'group A' feature and *two or more* 'group B' features.

Group A features after exclusion of joint trauma within the last 6 months (by history) and exclusion of inflammatory arthritis (by radiographs, history and laboratory parameters), are:

- i. Definite osteophyte formation
- ii. Full thickness cartilage loss

Group B features are:

- i. Subchondral bone marrow lesion or cyst *not* associated with meniscal or ligamentous attachments
- ii. Meniscal subluxation, maceration or degenerative (horizontal) tear

- iii. Partial thickness cartilage loss (where full thickness loss is not present)
- iv. Bone attrition

Definition of PF OA requires all of the following involving the patella and/or anterior femur:

- i. A definite osteophyte
- ii. Partial or full thickness cartilage loss

Q9) How should we make the diagnosis of knee osteoarthritis on a daily practical basis?

Steering group answer:

The clinical diagnosis of osteoarthritis can typically be made on the basis of the duration and character of the knee joint symptoms, patient history (including the presence of strong risk factors for osteoarthritis such as age, limb malalignment, obesity, heredity, prior knee injuries and surgeries), and findings from clinical examination. In the orthopaedic setting, weight-bearing semi-flexed knee radiographs (such as the Lyon Schuss or Rosenberg view) should be included in the work-up of the middle-aged or older patient with knee pain. A skyline patella view is also important for the detection of radiographic evidence of patellofemoral osteoarthritis. Please note that plain knee radiography does not necessarily capture early stages of symptomatic knee osteoarthritis.

Grade B

Q10) Does an unstable degenerative meniscus lesion cause knee symptoms?

Steering group answer:

While there is limited support in the literature that degenerative meniscus lesions considered to be unstable, e.g., flap tears, are truly causing knee symptoms, it is still plausible that, in some patients, torn meniscus parts from the degenerative lesion (by its displacement) may cause knee joint symptoms (fig 4).

Grade C

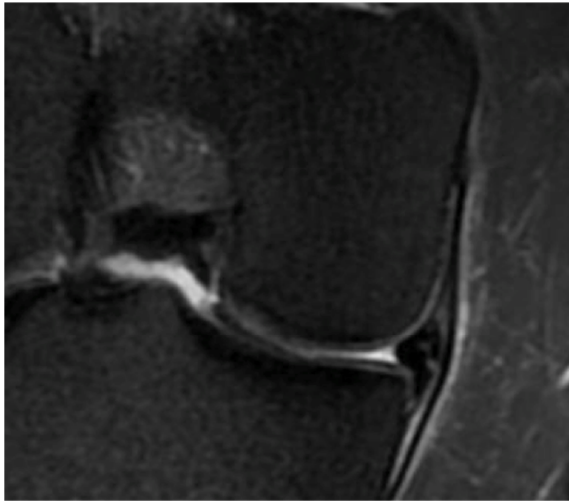


Figure 4: Degenerative Meniscus lesion of the medial meniscus with a flap subluxated in the tibial gutter which may cause knee symptoms

Literature review:

No doubt a meniscus tear can be unstable (74). However, importantly the hallmark of an unstable tear is the bucket-handle tear of typical *traumatic* origin, i.e., a *longitudinal* tear where the central torn part may dislocate into the central area of the knee and cause catching symptoms or locking of the knee. However, the evidence for such symptoms is more speculative and uncertain for the typical degenerative meniscus lesion. ‘Milder’ mechanical symptoms, i.e., no true locking, in the degenerative knee are often more unspecific than in the knee trauma patient. The symptoms are also often substantially fluctuating of nature. In the patient with the degenerate knee, symptoms may be instead related to knee osteoarthritis, e.g., uneven cartilage surfaces, synovitis, and bone marrow lesions. Further, there is little plausible rationale that the most typical degenerative meniscus lesion, i.e., a horizontal cleavage without a flap, would dislocate to cause true locking or catching symptoms (74). In a recent double-blinded randomized clinical trial the improvement with respect to mechanical symptoms was similar irrespective if the treatment was partial meniscus resection or a sham meniscus resection procedure for degenerative meniscus lesions (75). The only treatment that was different in the two treatment arms was the actual resection of the meniscus tissue as both groups had diagnostic arthroscopy before the randomization was made. These findings strongly suggest limited importance of the degenerative meniscus lesion *per se* as the source of symptoms.

Given the widespread belief regarding the validity of preoperative mechanical symptoms as an indication for knee arthroscopy in patients with a degenerative meniscus lesion (76-85),

there is as yet limited evidence to support such a policy. Matusue and Thomson (86) reported that 55% of patients 65 years of age or older with the preoperative symptoms of locking or catching reported the presence of these symptoms approximately eight years after partial meniscectomy. Similarly, McBride et al. (87) reported the alleviation of symptoms of locking in only 17% (1/6) of patients undergoing arthroscopic partial meniscectomy for a degenerative meniscus tear over a 35month follow-up. However, in patients with a *traumatic* meniscus tear, the success rate of APM in curing mechanical symptoms is reported to range from 76% (87) to 100% (88). In the patient with the degenerate knee, who *truly* has episodes of frequent locking and/or an extension deficit, a torn unstable meniscus must be considered as a plausible cause for these symptoms.

References:

1. Noble J. Lesions of the menisci. Autopsy incidence in adults less than fifty-five years old. J Bone Joint Surg Am. 1977;59(4):480-3.
2. Noble J, Hamblen DL. The pathology of the degenerate meniscus lesion. J Bone Joint Surg Br. 1975;57(2):180-6.
3. Hodler J, Haghighi P, Pathria MN, Trudell D, Resnick D. Meniscal changes in the elderly: correlation of MR imaging and histologic findings. Radiology. 1992;184(1):221-5.
4. Stoller DW, Martin C, Crues JV, 3rd, Kaplan L, Mink JH. Meniscal tears: pathologic correlation with MR imaging. Radiology. 1987;163(3):731-5.
5. Englund M, Guermazi A, Gale D, Hunter DJ, Aliabadi P, Clancy M, et al. Incidental meniscal findings on knee MRI in middle-aged and elderly persons. N Engl J Med. 2008;359(11):1108-15.
6. Poehling GG, Ruch DS, Chabon SJ. The landscape of meniscal injuries. Clin Sports Med. 1990;9(3):539-49.
7. Kumm J, Turkiewicz A, Guermazi A, Roemer F, Englund M. Natural history of intrameniscal signal on knee magnetic resonance imaging: Six years of data from the Osteoarthritis Initiative. Radiology. 2015:(in press).
8. Englund M. The role of biomechanics in the initiation and progression of OA of the knee. Best Pract Res Clin Rheumatol. 2010;24(1):39-46.
9. Englund M, Felson DT, Guermazi A, Roemer FW, Wang K, Crema MD, et al. Risk factors for medial meniscal pathology on knee MRI in older US adults: a multicentre prospective cohort study. Ann Rheum Dis. 2011;70(10):1733-9.



10. Rytter S, Jensen LK, Bonde JP, Jurik AG, Egund N. Occupational kneeling and meniscal tears: a magnetic resonance imaging study in floor layers. *J Rheumatol*. 2009;36(7):1512-9.
11. Pauli C, Grogan SP, Patil S, Otsuki S, Hasegawa A, Koziol J, et al. Macroscopic and histopathologic analysis of human knee menisci in aging and osteoarthritis. *Osteoarthritis Cartilage*. 2011;19(9):1132-41.
12. Berthiaume MJ, Raynauld JP, Martel-Pelletier J, Labonte F, Beaudoin G, Bloch DA, et al. Meniscal tear and extrusion are strongly associated with progression of symptomatic knee osteoarthritis as assessed by quantitative magnetic resonance imaging. *Ann Rheum Dis*. 2005;64(4):556-63.
13. Hunter DJ, Zhang YQ, Niu JB, Tu X, Amin S, Clancy M, et al. The association of meniscal pathologic changes with cartilage loss in symptomatic knee osteoarthritis. *Arthritis Rheum*. 2006;54(3):795-801.
14. Podsiadlo P, Dahl L, Englund M, Lohmander LS, Stachowiak GW. Differences in trabecular bone texture between knees with and without radiographic osteoarthritis detected by fractal methods. *Osteoarthritis Cartilage*. 2008;16(3):323-9.
15. Kraus VB, Feng S, Wang S, White S, Ainslie M, Brett A, et al. Trabecular morphometry by fractal signature analysis is a novel marker of osteoarthritis progression. *Arthritis Rheum*. 2009;60(12):3711-22.
16. Wolski M, Podsiadlo P, Stachowiak GW, Lohmander LS, Englund M. Differences in trabecular bone texture between knees with and without radiographic osteoarthritis detected by directional fractal signature method. *Osteoarthritis Cartilage*. 2010;18(5):684-90.
17. Lo GH, Niu J, McLennan CE, Kiel DP, McLean RR, Guermazi A, et al. Meniscal damage associated with increased local subchondral bone mineral density: a Framingham study. *Osteoarthritis Cartilage*. 2008;16(2):261-7.
18. Englund M, Guermazi A, Roemer FW, Yang M, Zhang Y, Nevitt MC, et al. Meniscal pathology on MRI increases the risk for both incident and enlarging subchondral bone marrow lesions of the knee: the MOST Study. *Ann Rheum Dis*. 2010;69(10):1796-802.
19. De Smet AA, Norris MA, Yandow DR, Quintana FA, Graf BK, Keene JS. MR diagnosis of meniscal tears of the knee: importance of high signal in the meniscus that extends to the surface. *AJR Am J Roentgenol*. 1993;161(1):101-7.
20. De Smet AA, Tuite MJ. Use of the "two-slice-touch" rule for the MRI diagnosis of meniscal tears. *AJR Am J Roentgenol*. 2006;187(4):911-4.



21. Englund M, Guermazi A, Lohmander SL. The role of the meniscus in knee osteoarthritis: a cause or consequence? *Radiol Clin North Am.* 2009;47(4):703-12.
22. Fox MG. MR imaging of the meniscus: review, current trends, and clinical implications. *Radiol Clin North Am.* 2007;45(6):1033-53, vii.
23. Newman AP, Daniels AU, Burks RT. Principles and decision making in meniscal surgery. *Arthroscopy.* 1993;9(1):33-51.
24. Kornaat PR, Bloem JL, Ceulemans RY, Riyazi N, Rosendaal FR, Nelissen RG, et al. Osteoarthritis of the knee: association between clinical features and MR imaging findings. *Radiology.* 2006;239(3):811-7.
25. Link TM, Steinbach LS, Ghosh S, Ries M, Lu Y, Lane N, et al. Osteoarthritis: MR imaging findings in different stages of disease and correlation with clinical findings. *Radiology.* 2003;226(2):373-81.
26. Bhattacharyya T, Gale D, Dewire P, Totterman S, Gale ME, McLaughlin S, et al. The clinical importance of meniscal tears demonstrated by magnetic resonance imaging in osteoarthritis of the knee. *J Bone Joint Surg Am.* 2003;85-A(1):4-9.
27. Noble J, Erat K. In defence of the meniscus. A prospective study of 200 meniscectomy patients. *J Bone Joint Surg Br.* 1980;62-B(1):7-11.
28. Felson DT, Chaisson CE, Hill CL, Totterman SM, Gale ME, Skinner KM, et al. The association of bone marrow lesions with pain in knee osteoarthritis. *Ann Intern Med.* 2001;134(7):541-9.
29. Sihvonen R, Paavola M, Malmivaara A, Itala A, Joukainen A, Nurmi H, et al. Arthroscopic partial meniscectomy versus sham surgery for a degenerative meniscal tear. *N Engl J Med.* 2013;369(26):2515-24.
30. Englund M, Niu J, Guermazi A, Roemer FW, Hunter DJ, Lynch JA, et al. Effect of meniscal damage on the development of frequent knee pain, aching, or stiffness. *Arthritis Rheum.* 2007;56(12):4048-54.
31. Zhang Y, Nevitt M, Niu J, Lewis C, Torner J, Guermazi A, et al. Fluctuation of knee pain and changes in bone marrow lesions, effusions, and synovitis on magnetic resonance imaging. *Arthritis Rheum.* 2011;63(3):691-9.
32. Roemer FW, Guermazi A, Hunter DJ, Niu J, Zhang Y, Englund M, et al. The association of meniscal damage with joint effusion in persons without radiographic osteoarthritis: the Framingham and MOST osteoarthritis studies. *Osteoarthritis Cartilage.* 2009;17(6):748-53.



33. Ashraf S, Wibberley H, Mapp PI, Hill R, Wilson D, Walsh DA. Increased vascular penetration and nerve growth in the meniscus: a potential source of pain in osteoarthritis. *Ann Rheum Dis.* 2011;70(3):523-9.
34. De Smet AA, Graf BK, del Rio AM. Association of parameniscal cysts with underlying meniscal tears as identified on MRI and arthroscopy. *AJR Am J Roentgenol.* 2011;196(2):W180-6.
35. Campbell SE, Sanders TG, Morrison WB. MR imaging of meniscal cysts: incidence, location, and clinical significance. *AJR Am J Roentgenol.* 2001;177(2):409-13.
36. Wu CC, Hsu YC, Chiu YC, Chang YC, Lee CH, Shen HC, et al. Parameniscal cyst formation in the knee is associated with meniscal tear size: an MRI study. *Knee.* 2013;20(6):556-61.
37. Wenger A, Englund M, Wirth W, Hudelmaier M, Kwok K, Eckstein F. Relationship of 3D meniscal morphology and position with knee pain in subjects with knee osteoarthritis: a pilot study. *Eur Radiol.* 2011.
38. Herrlin S, Hallander M, Wange P, Weidenhielm L, Werner S. Arthroscopic or conservative treatment of degenerative medial meniscal tears: a prospective randomised trial. *Knee Surg Sports Traumatol Arthrosc.* 2007;15(4):393-401.
39. Moseley JB, O'Malley K, Petersen NJ, Menke TJ, Brody BA, Kuykendall DH, et al. A controlled trial of arthroscopic surgery for osteoarthritis of the knee. *N Engl J Med.* 2002;347(2):81-8.
40. Kirkley A, Birmingham TB, Litchfield RB, Giffin JR, Willits KR, Wong CJ, et al. A randomized trial of arthroscopic surgery for osteoarthritis of the knee. *N Engl J Med.* 2008;359(11):1097-107.
41. Shrier I, Boudier-Reveret M, Fahmy K. Understanding the different physical examination tests for suspected meniscal tears. *Curr Sports Med Rep.* 2010;9(5):284-9.
42. Solomon DH, Simel DL, Bates DW, Katz JN, Schaffer JL. The rational clinical examination. Does this patient have a torn meniscus or ligament of the knee? Value of the physical examination. *JAMA.* 2001;286(13):1610-20.
43. Hing W, White S, Reid D, Marshall R. Validity of the McMurray's Test and Modified Versions of the Test: A Systematic Literature Review. *J Man Manip Ther.* 2009;17(1):22-35.
44. Rytter S, Jensen LK, Bonde JP. Clinical knee findings in floor layers with focus on meniscal status. *BMC Musculoskelet Disord.* 2008;9:144.



45. Stoppiello LA, Mapp PI, Wilson D, Hill R, Scammell BE, Walsh DA. Structural associations of symptomatic knee osteoarthritis. *Arthritis Rheumatol.* 2014;66(11):3018-27.
46. Sihvonen R, Paavola M, Malmivaara A, Jarvinen TL. Finnish Degenerative Meniscal Lesion Study (FIDELITY): a protocol for a randomised, placebo surgery controlled trial on the efficacy of arthroscopic partial meniscectomy for patients with degenerative meniscus injury with a novel 'RCT within-a-cohort' study design. *BMJ Open.* 2013;3(3).
47. Seedhom BB, Dowson D, Wright V. Proceedings: Functions of the menisci. A preliminary study. *Ann Rheum Dis.* 1974;33(1):111.
48. Shrive NG, O'Connor JJ, Goodfellow JW. Load-bearing in the knee joint. *Clin Orthop.* 1978(131):279-87.
49. Seedhom BB, Hargreaves DJ. Transmission of the load in the knee joint with special reference to the role of the meniscus. Part I+II. *Eng Med.* 1979;4:207-28.
50. Walker PS, Erkman MJ. The role of the menisci in force transmission across the knee. *Clin Orthop.* 1975(109):184-92.
51. Fukubayashi T, Kurosawa H. The contact area and pressure distribution pattern of the knee. A study of normal and osteoarthrotic knee joints. *Acta Orthop Scand.* 1980;51(6):871-9.
52. Kurosawa H, Fukubayashi T, Nakajima H. Load-bearing mode of the knee joint: physical behavior of the knee joint with or without menisci. *Clin Orthop.* 1980(149):283-90.
53. Englund M, Guermazi A, Roemer FW, Aliabadi P, Yang M, Lewis CE, et al. Meniscal tear in knees without surgery and the development of radiographic osteoarthritis among middle-aged and elderly persons: The Multicenter Osteoarthritis Study. *Arthritis Rheum.* 2009;60(3):831-9.
54. Chang A, Moisisio K, Chmiel JS, Eckstein F, Guermazi A, Almagor O, et al. Subregional effects of meniscal tears on cartilage loss over 2 years in knee osteoarthritis. *Ann Rheum Dis.* 2011;70(1):74-9.
55. Johnson TC, Evans JA, Gilley JA, DeLee JC. Osteonecrosis of the knee after arthroscopic surgery for meniscal tears and chondral lesions. *Arthroscopy.* 2000;16(3):254-61.
56. Muscolo DL, Costa-Paz M, Makino A, Ayerza MA. Osteonecrosis of the knee following arthroscopic meniscectomy in patients over 50-years old. *Arthroscopy.* 1996;12(3):273-9.



57. Lee DH, Lee BS, Kim JM, Yang KS, Cha EJ, Park JH, et al. Predictors of degenerative medial meniscus extrusion: radial component and knee osteoarthritis. *Knee Surg Sports Traumatol Arthrosc.* 2011;19(2):222-9.
58. Kenny C. Radial displacement of the medial meniscus and Fairbank's signs. *Clin Orthop Relat Res.* 1997(339):163-73.
59. Sugita T, Kawamata T, Ohnuma M, Yoshizumi Y, Sato K. Radial displacement of the medial meniscus in varus osteoarthritis of the knee. *Clin Orthop Relat Res.* 2001(387):171-7.
60. Gale DR, Chaisson CE, Totterman SM, Schwartz RK, Gale ME, Felson D. Meniscal subluxation: association with osteoarthritis and joint space narrowing. *Osteoarthritis Cartilage.* 1999;7(6):526-32.
61. Sharma L, Eckstein F, Song J, Guermazi A, Prasad P, Kapoor D, et al. Relationship of meniscal damage, meniscal extrusion, malalignment, and joint laxity to subsequent cartilage loss in osteoarthritic knees. *Arthritis Rheum.* 2008;58(6):1716-26.
62. Hunter DJ, Zhang YQ, Tu X, Lavalley M, Niu JB, Amin S, et al. Change in joint space width: hyaline articular cartilage loss or alteration in meniscus? *Arthritis Rheum.* 2006;54(8):2488-95.
63. Hunter DJ, Buck R, Vignon E, Eckstein F, Brandt K, Mazzuca SA, et al. Relation of regional articular cartilage morphometry and meniscal position by MRI to joint space width in knee radiographs. *Osteoarthritis Cartilage.* 2009;17(9):1170-6.
64. Bloecker K, Wirth W, Hunter DJ, Duryea J, Guermazi A, Kwoh CK, et al. Contribution of regional 3D meniscus and cartilage morphometry by MRI to joint space width in fixed flexion knee radiography--a between-knee comparison in subjects with unilateral joint space narrowing. *Eur J Radiol.* 2013;82(12):e832-9.
65. Bloecker K, Guermazi A, Wirth W, Benichou O, Kwoh CK, Hunter DJ, et al. Tibial coverage, meniscus position, size and damage in knees discordant for joint space narrowing - data from the Osteoarthritis Initiative. *Osteoarthritis Cartilage.* 2013;21(3):419-27.
66. Prove S, Charrois O, Dekeuwer P, Fallet L, Beaufils P. [Comparison of the medial femorotibial joint space before and immediately after meniscectomy]. *Rev Chir Orthop Reparatrice Appar Mot.* 2004;90(7):636-42.
67. Ayral X, Bonvarlet JP, Simonnet J, Auleley GR, Dougados M, Ravaud P. Influence of medial meniscectomy on tibiofemoral joint space width. *Osteoarthritis Cartilage.* 2003;11(4):285-9.

68. Kurosawa H, Fukubayashi T, Nakajima H. Load-bearing mode of the knee joint: physical behavior of the knee joint with or without menisci. *Clin Orthop Relat Res.* 1980(149):283-90.
69. Shrive NG, O'Connor JJ, Goodfellow JW. Load-bearing in the knee joint. *Clin Orthop Relat Res.* 1978(131):279-87.
70. Walker PS, Erkman MJ. The role of the menisci in force transmission across the knee. *Clin Orthop Relat Res.* 1975(109):184-92.
71. Bedson J, Croft PR. The discordance between clinical and radiographic knee osteoarthritis: a systematic search and summary of the literature. *BMC Musculoskeletal Disord.* 2008;9:116.
72. Guermazi A, Niu J, Hayashi D, Roemer FW, Englund M, Neogi T, et al. Prevalence of abnormalities in knees detected by MRI in adults without knee osteoarthritis: population based observational study (Framingham Osteoarthritis Study). *BMJ.* 2012;345:e5339.
73. Hunter DJ, Arden N, Conaghan PG, Eckstein F, Gold G, Grainger A, et al. Definition of osteoarthritis on MRI: results of a Delphi exercise. *Osteoarthritis Cartilage.* 2011;19(8):963-9.
74. Boxheimer L, Lutz AM, Zanetti M, Treiber K, Labler L, Marincek B, et al. Characteristics of displaceable and nondisplaceable meniscal tears at kinematic MR imaging of the knee. *Radiology.* 2006;238(1):221-31.
75. Sihvonen R, Englund M, Turkiewicz A, Jarvinen TL, Finnish Degenerative Meniscal Lesion Study G. Mechanical Symptoms and Arthroscopic Partial Meniscectomy in Patients With Degenerative Meniscus Tear: A Secondary Analysis of a Randomized Trial. *Ann Intern Med.* 2016.
76. Richmond JC. Is there a role for arthroscopy in the treatment of osteoarthritis? *Arthroscopy.* 2010;26(2):143-4.
77. Stuart MJ, Lubowitz JH. What, if any, are the indications for arthroscopic debridement of the osteoarthritic knee? *Arthroscopy.* 2006;22(3):238-9.
78. Felson DT. Arthroscopy as a treatment for knee osteoarthritis. *Best Pract Res Clin Rheumatol.* 2010;24(1):47-50.
79. Richmond J, Hunter D, Irrgang J, Jones MH, Levy B, Marx R, et al. Treatment of osteoarthritis of the knee (nonarthroplasty). *J Am Acad Orthop Surg.* 2009;17(9):591-600.
80. Conaghan PG, Dickson J, Grant RL. Care and management of osteoarthritis in adults: summary of NICE guidance. *BMJ.* 2008;336(7642):502-3.



81. Zhang W, Moskowitz RW, Nuki G, Abramson S, Altman RD, Arden N, et al. OARSI recommendations for the management of hip and knee osteoarthritis, part I: critical appraisal of existing treatment guidelines and systematic review of current research evidence. *Osteoarthritis Cartilage*. 2007;15(9):981-1000.
82. Price A, Beard D. Arthroscopy for degenerate meniscal tears of the knee. *BMJ*. 2014;348:g2382.
83. Krych AJ, Carey JL, Marx RG, Dahm DL, Sennett BJ, Stuart MJ, et al. Does arthroscopic knee surgery work? *Arthroscopy*. 2014;30(5):544-5.
84. Krych AJ, Stuart MJ, Levy BA. Arthroscopic partial meniscectomy for degenerative meniscal tear. *N Engl J Med*. 2014;370(13):1259.
85. Jevsevar DS, Yates AJ, Jr., Sanders JO. Arthroscopic partial meniscectomy for degenerative meniscal tear. *N Engl J Med*. 2014;370(13):1260.
86. Matsusue Y, Thomson NL. Arthroscopic partial medial meniscectomy in patients over 40 years old: a 5- to 11-year follow-up study. *Arthroscopy*. 1996;12(1):39-44.
87. McBride GG, Constance RM, Hofmann AA, Carson RW. Arthroscopic partial medial meniscectomy in the older patient. *J Bone Joint Surg Am*. 1984;66(4):547-51.
88. Jackson RW, Rouse DW. The results of partial arthroscopic meniscectomy in patients over 40 years of age. *J Bone Joint Surg Br*. 1982;64(4):481-5.

III. Management

Q1) Are functional outcomes of Arthroscopic Partial Meniscectomy (APM) and Non Operative Treatment different, based on Osteoarthritic (OA) Status?

Steering group answer:

No study compared OA knees with non-OA knees regarding the treatment. Thus, data is lacking on the relationship between the duration of symptoms, stage and location of OA (...etc) and the treatment outcomes.

Grade D

Literature review:

Study	Inclusion criteria (arthritis)	Conclusion
<i>Moseley et al [1]</i>	KL \leq 4	Debridement = Sham
<i>Kirkley et al [2]</i>	KL 2-4	Debridement = PT
<i>Herrlin et al [3]</i>	AI \leq 1	APM = PT
<i>Katz et al [4]</i>	KL \leq 1	APM=PT
<i>Yim et al [5]</i>	KL \leq 1	APM=PT
<i>Sihvonen et al [6]</i>	KL \leq 1	APM= Sham
<i>Gauffin et al [7]</i>	KL \leq 2 + Mechanical Sympt	APM+PT > PT

Two RCT's specifically focused on OA knees and four on degenerative meniscus tears: similar results.

1. RCT OA-Knees

[1]Moseley JB, O'Malley K, Petersen NJ, Menke TJ, Brody BA, Kuykendall DH,



Hollingsworth JC, Ashton CM, Wray NP. *A controlled trial of arthroscopic surgery for osteoarthritis of the knee*. N Engl J Med. 2002 **Level of evidence I**

The study arms included arthroscopic debridement, arthroscopic lavage and a sham procedure that involved skin incisions but no entry of surgical equipment into the joint. Randomization was done in blocks defined by radiographic OA severity. To grade OA severity, the investigators rated each of the three major knee compartments from 0 to 4 (with 4 = severe joint space narrowing according to the Kellgren-Lawrence scale) and the compartments were summed to give a summary OA severity grade ranging from 0–12. Those patients with summary scores of 9 or greater were excluded. Forty-four percent of eligible subjects agreed to enroll in the trial, even though they knew they had a one-in-three chance of receiving sham surgery. The authors randomized 180 subjects between 1995 and 1998 and followed the subjects for two years before “unblinding” both them and their assessors. The authors documented early pain reduction in all three groups followed by essentially no change in pain through two years of follow-up. At no point were there clinically important differences among the three arms. The Moseley trial has left an enormous legacy. First, it established that arthroscopic lavage and debridement were no better than sham surgery in the management of OA. Second, these investigators demonstrated that a sham trial was indeed feasible, at least in the Veterans Administration system. Finally, the study raised ethical questions about the appropriateness of sham surgery, which gave rise to a lively debate that remains unresolved. Because the study did not include an arm that received no surgical intervention at all, the investigators were unable to comment on whether simply doing surgery (real or sham) was more efficacious than a non-operative placebo intervention.

[2]Kirkley A, Birmingham TB, Litchfield RB, Giffin JR, Willits KR, Wong CJ, Feagan BG, Donner A, Griffin SH, D’Ascanio LM, Pope JE, Fowler PJ. *A randomized trial of arthroscopic surgery for osteoarthritis of the knee*. N Engl J Med. 2008 **Level of evidence I**.

The investigators included patients with radiographic knee OA, excluding those with suspected or confirmed bucket handle tears and those with far advanced OA (Grade 4 changes on the Kellgren-Lawrence scale in two or more compartments). Subjects were randomized to either a standardized physical therapy (PT) regimen or the PT regimen along with arthroscopic debridement. Articular cartilage was debrided in 97% of subjects randomized to surgery and the meniscus was debrided in 81%, testifying to the ubiquity of cartilage and meniscal flaps, tears, and debris in this study sample. Outcomes were assessed with the WOMAC pain and function scores.

Remarkably, only 11% of screened subjects refused to participate. Another 21% were ineligible and 68% were randomized. While the surgical group had an initial improvement in symptoms compared to the PT group at the 3-month follow-up visit, there were no differences in improvement between the two groups at any subsequent visits. Also as observed by Moseley, this trial did not identify a statistically significant or clinically meaningful difference in pain or functional status between those randomized to the PT regimen and those randomized to APM along with PT. A pre-specified analysis of subjects with complaints of locking and clicking also failed to demonstrate differences in outcome between surgical and non-operative therapy. Thus, the Kirkley study built upon the results of Moseley and colleagues and, like Moseley, also failed to demonstrate that arthroscopic debridement is superior to a typical PT regimen in patients with moderately advanced knee OA.

2. RCT Meniscus Lesion + early OA

The major indication for arthroscopy in the setting of knee OA is a symptomatic meniscal tear. Whilst the Kirkley study did not exclude subjects with imaging or symptomatic evidence of meniscus tear, the focus of the study was OA per se, not meniscal tear. Indeed, subjects were recruited on the basis of symptomatic OA, not suspected symptomatic meniscal tear. Thus, the question of whether surgery is more effective than a standardized non-operative regimen in patients with symptomatic meniscal tear and concomitant knee OA remains unanswered even after the publication of these two landmark studies.

A number of non-randomized studies had documented the value of arthroscopic partial meniscectomy (APM) in patients with meniscus tear; however, as with the early literature on surgery for OA, these studies were limited by uncontrolled observations of heterogeneous interventions performed on generally small samples. Further, and perhaps most important, much of the literature on surgery for meniscus tears had been conducted in younger persons with otherwise normal knees. Yet, increasingly APM was being performed on middle aged and older individuals with concomitant knee OA. It is unclear whether the presentation, natural history and optimal treatment for these degenerative lesions differ from those associated with traumatic tears in persons in their 20s and 30s. Four studies have been published in the last few years that begin to address these questions about the role of surgery in people with a meniscus lesion and concomitant OA.

[3]Herrlin SV, Wange PO, Lapidus G, Hållander M, Werner S, Weidenhielm L. *Is*



arthroscopic surgery beneficial in treating non-traumatic, degenerative medial meniscal tears? A five year follow-up. Knee Surg Sports Traumatol Arthrosc. 2013 **Level of evidence I.**

Herrlin et al enrolled 96 subjects 45–64 years of age with knee pain, meniscus lesion on MRI and radiographic OA with, at most, **minor joint space narrowing (Ahlbäck 0-1)**. Subjects were randomized to a rigorous exercise regimen alone or to the same exercise regimen with arthroscopic partial meniscectomy. The exercise regimen was supervised by a physical therapist twice a week for two months. The program was performed twice a week during a period of 8 weeks each patient followed a standardised exercise programme with the possibility for individual adaptation. The goal of the exercise programme was to reduce pain, restore full ROM and improve knee function. It consisted of exercises for improving muscle strength and endurance, muscle flexibility as well as balance and proprioception. Outcomes were assessed at 2, 6, 24 and 60 months with the KOOS (Knee Injury and Osteoarthritis Outcome Score) measures of pain, ADL, recreational and sports activities and knee related quality of life. **In intention to treat analyses, the two randomized groups both improved considerably over the first six months and maintained improvements in pain and functional status over 60 months.** The findings did not reveal statistically significant or clinically relevant differences between the two randomized groups at any time point. **Of note, however, about 30% of the subjects randomized to the non-operative arm had persistent pain and crossed over to have surgery.** These subjects who crossed over to have surgery had similar outcomes to those randomized to receive surgery at the outset. The investigators suggested that their findings supported initial treatment with non-operative therapy in middle-aged individuals with symptomatic meniscal tear and concomitant OA, with subsequent surgery in those who failed to improve.

[4]Katz JN, Brophy RH, Chaisson CE, et al. *Surgery versus physical therapy for a meniscal tear and osteoarthritis.* N Engl J Med. 2013 **Level of evidence I.**

The MeTeOR (Meniscal Tear in Osteoarthritis Research) Trial shared many design similarities to the study of Herrlin et al. MeTeOR enrolled patients age 45 or greater with meniscus lesion documented on MRI and **underlying osteoarthritic change (Kellgren-Lawrence 0-3)** documented on radiograph or MRI. Patients with Kellgren-Lawrence grade 4 OA (more than 50% joint space narrowing) were excluded. Subjects were randomized to receive either a standardized PT regimen that emphasized strengthening or arthroscopic partial meniscectomy with postoperative PT. A three stage structured program was designed

to address inflammation, range of motion, concentric and eccentric muscle strength, muscle-length restrictions, aerobic conditioning (e.g., with the use of a bicycle, elliptical machine, or treadmill), functional mobility, and proprioception and balance. The primary outcome was the change in WOMAC Function Scale between the baseline and at six months. Secondary outcomes included the KOOS Pain Scale and these same outcomes at 12 months. 351 subjects were randomized in seven centers. The results documented that subjects randomized to APM and those randomized to PT **both improved considerably in the first six months with no statistically significant or clinically important differences between randomized groups at six or twelve months of follow up**. As in Herrlin et al, however, **about 30% of MeTeOR subjects crossed over from non-operative therapy to surgery**.

[5]Yim J-H, Seon J-K, Song E-K, Choi J-I, Kim M-C, Lee K-B, Seo H-Y. *A comparative study of meniscectomy and nonoperative treatment for degenerative horizontal tears of the medial meniscus*. Am J Sports Med. 2013 **Level of evidence I**.

In 2013, Yim et al published a randomized controlled trial of arthroscopic partial meniscectomy vs. a non-operative regimen focused on strengthening in 102 subjects with **symptomatic meniscal tear with no OA (Kellgren-Lawrence 0-1)**. The non-operative treatment included analgesics, nonsteroidal anti-inflammatory drugs (NSAIDs), or muscle relaxants, depending on clinical symptoms for the first 2 weeks. In addition, patients underwent supervised physical exercise to improve muscle strength, endurance, and flexibility for 60 minutes per session, 3 times weekly, for 3 weeks. After that, patients were provided with a home exercise program, which they conducted unsupervised for 8 weeks. The home exercise program consisted of daily isometric and isotonic muscle exercises.

Patients were followed for 24 months with a similar set of outcome assessments as in the Herrlin and MeTeOR trials. Yim et al also found that in the intention to treat analysis, both groups improved considerably with no clinically important or statistically significant differences in improvement in any of the key outcome measures. In contrast to the other two studies, however, only one subject in the study of Yim et al crossed over from the non-operative arm to receive surgery. In addition, it is noteworthy that over 60% of eligible patients agreed to participate in Yim's study, compared to < 30% in MeTeOR. The reason(s) for these differences remain unclear and warrant further investigation.

[6]Sihvonen R, Paavola M, Malmivaara A, Itälä A, Joukainen A, Nurmi H, Kalske J, Järvinen TLN, Finnish Degenerative Meniscal Lesion Study (FIDELITY) Group. *Arthroscopic partial meniscectomy versus sham surgery for a degenerative meniscal tear*. N

Engl J Med. 2013 **Level of evidence I.**

In late 2013 Sihvonen and colleagues published a randomized controlled trial of arthroscopic partial meniscectomy vs. sham meniscectomy procedure for degenerative meniscus lesion for patients aged 35 to 65 years with symptoms of **degenerative medial meniscus lesion and no knee OA (Kellgren-Lawrence 0-1)**. Subjects were assigned to either arthroscopic partial meniscectomy or arthroscopic surgery with sham meniscal resection. **In both arms showed substantial improvement in pain and function in the first two months following surgery with no significant or clinically important differences between arms in the change from baseline to 12 months in any primary outcome.**

[7]Gauffin H, Tagesson S, Meunier A, Magnusson H, Kvist J. Knee arthroscopic surgery is beneficial to middle-aged patients with meniscal symptoms: a prospective, randomised, single-blinded study. *Osteoarthritis Cartilage*. 2014 **Level of evidence I.**

In 2014, Gauffin et al [7] presented a single-blinded RCT including mild-aged (45-60 yr) patients with an **“injured” meniscus** (onset of pain; daily joint catching; and joint locking for more than 2 seconds over the past month)**and “non arthritic” (Kellgren-Lawrence <2) knees** : after a four weeks of functional treatment, patients were divided into two groups **surgery (within four week after physician appointment) or functional treatment (3 months)**. Participants were asked to perform the exercise programme in the gym, without supervision from a physiotherapist. A home-based exercise programme was provided as an alternative. The exercise program was to be performed twice per week.

150 patients were included in this interesting series, even if some clinical outcomes were different between the two groups during the baseline evaluation (Pain Koo(s) subscore), the authors concluded that **for these patients (meniscal symptoms / no OA) APM might result in better clinical results (KOOS/EuroQOL 5D/VAS) at 3 and 12 months.**

Q2) What is the patient population defined by the RCT studies?

Steering group answer:

Based on RCT inclusion criteria, the studies include patients with:

- *Age \geq 35 years. Grade A. [6]*
- *Male or female. Grade A. [1-7]*
- *Daily or almost daily Knee Pain > 1 month. Grade A. [5]*
- *Medial or lateral degenerative meniscus lesion*

- *With or without mechanical symptoms.*

Grade A [7]

Literature review:

Study	Patients' Age	Inclusion criteria (arthritis)
<i>Moseley et al [1]</i>	51+/-11	\$>6Mo KL≤4
<i>Kirkley study [2]</i>	59+/-10 yr	\$>3Mo KL 2–4
<i>Herrlin et al [3]</i>	45–64 yr	\$>2Mo AI ≤1 Medial Tear MRI
<i>Katz et al [4]</i>	45–64 yr	\$>2Mo AI ≤1 Medial Tear MRI
<i>Yim et al [5]</i>	43-62	\$>1Mo KL ≤1 Medial Tear MRI
<i>Sihvonen et al [6]</i>	35-65	\$>3Mo KL<1 Medial Tear MRI
<i>Gauffin et al [7]</i>	45-64	\$>3Mo AI<1 Mechanical Sympt

Q3) What does non-operative treatment mean?

Steering group answer:

- 1. No evidence of which time/type of non-operative treatment should be proposed.*
- 2. In the current literature, RCTs have proposed various rehabilitation protocols, however non-operative treatment also could consist of NSAID (if no contraindication), intra-articular injection* , physiotherapy and/or home exercises for three to six months. Grade B. [3,5,8-11]*

3. It is important to notice that no study has focused on functional outcomes of non-operative treatment vs Placebo (or nothing).

***Benefit or risk of corticoid intra articular injection has to be discussed regarding the risk of hidden osteonecrosis. Efficacy of hyaluronic acid injection is controversial.**

Literature review:

Study	Type of Rehab	Duration
<i>Østerås et al [8]</i>	<i>See appendix</i>	<i>12-16 weeks</i>
<i>Stensrud et al [9]</i>	<i>See appendix</i>	<i>12 weeks</i>
<i>Herrlin et al [3]</i>	<i>See appendix</i>	<i>8 weeks</i>
<i>Yim et al [5]</i>	<i>See appendix</i>	<i>8 weeks</i>
<i>Neogi et al [10]</i>		<i>12 weeks + home exercises</i>
<i>Rimington et al [11]</i>	<i>AINS 4 weeks then Surgery or Rehab</i>	<i>4 weeks AINS +/- rehab long term</i>

[8]Osteras H, Osteras B, Torstensen TA. *Medical Exercise Therapy is Effective After Arthroscopic Surgery of Degenerative Meniscus of the Knee: A Randomized Controlled Trial.* J Clin Med Res. 2012 **Level of evidence I.**

Osteras et al designed a prospective randomized controlled clinical trial. Over a 4 month period, 70 participants were randomly assigned into a high repetitive, high dosage medical exercise therapy group (EG) (n = 36) or into a control group (CG) (n = 34) exercise program focusing on coordination and muscle function training, along with pain modification exercise therapy. The rehabilitation period was 3 months, and the subjects performed the exercise program 3 times per week. Pain was a composite score of visual analogue scale (VAS). Function was measured with a functional assessment questionnaire (KOOS). Muscle strength was measured with a five repetition maximum test of quadriceps femoris. Prognostic variables were similar between the groups at baseline. Five (7%) people dropped out during the treatment period. The EG achieved significantly better outcome effects than the CG at pain (VAS reduced 1.9 in EG and 0.6 in CG) and function (KOOS decreased 18 in EG and only 6 in CG).

[9]Stensrud S, Roos EM, Risberg MA. *A 12-week exercise therapy program in middle-aged patients with degenerative meniscus tears: a case series with 1-year follow-up.* J Orthop Sports PhysTher. 2012 **Level of evidence IV.**

82 patients with a symptomatic degenerative meniscus lesion and no or mild radiographic OA. The patients were randomly assigned to a supervised neuromuscular and strength exercise program or arthroscopic partial meniscectomy. The exercise therapy program consisted of progressive neuromuscular and strength exercises over 12 weeks, performed during a minimum of two and a maximum of three sessions per week. Neuromuscular exercises were designed to improve the position of the trunk and lower limbs relative to one another, as well as the quality of movement performance, whilst dynamically and functionally strengthening the lower-limb muscles. The exercise program resulted significant change (greater than APM) in knee extension peak torque from baseline to follow-up and also all other strength variables, except for total work knee flexion. There were statistically significant differences favouring the exercise therapy group.

[10]Neogi DS, Kumar A, Rijal L, Yadav CS, Jaiman A, Nag HL. *Role of nonoperative treatment in managing degenerative tears of the medial meniscus posterior root.* J OrthopTraumatol Off J ItalSocOrthopTraumatol. 2013 **Level of evidence IV.**

In this series patients were treated by a short course of analgesics daily for up to 6 weeks and then as required during follow-up, as well as a 12-week supervised exercise program followed by a home exercise program.

The appendix 1 presents a proposal of functional treatment designed by the steering group regarding actual literature rehabilitation protocol for degenerative meniscus lesions.

[12]Dorfmann H, Labaune D. *Knee arthroscopy: role of the arthroscopist in prescription. Report of a 3-year survey.* Rev ChirOrthopReparatriceAppar Mot. 1990 **Level of evidence IV.**

Dorfmann et al, found out that out of 765 patients suffering from a meniscus lesion who were not arthroscopied a large proportion improved their symptoms spontaneously (even without PT) and only 18 (4.7 per cent) required secondary arthroscopy.

[13]Hede A1, Hempel-Poulsen S, Jensen JS.

Symptoms and level of sports activity in patients awaiting arthroscopy for meniscus lesions of the knee. J Bone Joint Surg Am. 1990 **Level of evidence IV.**

In this study 36 patients who had symptoms suggestive of lesions of the meniscus of the knee were put on a waiting list for arthroscopy. After six to twenty-four months after being placed on the waiting list, none of the thirty-six patients had worse symptoms: four had no change, nine had no symptoms, and the remaining twenty-three had partial relief of symptoms. By the time of admission to the hospital, fourteen patients had decided not to go ahead with the arthroscopy. Of the twenty-two patients who had an arthroscopy, a meniscal abnormality was found in twelve. In two of these, a healed meniscus lesion was found.

Q 4) What is the rate of conversion to surgery in those patients undergoing non operative treatment?

Steering group answer:

Non Operative treatment is converted to surgery (cross – over) in 0 to 35% of the patients.

Grade A. [3-6,11,14]

This cross-over rate has to be compared to the rate of arthroscopic treatment failure.

Literature review:

One trial [5] did not report crossovers to the surgical arm. Of the trials that did report cross-over, Herrlin et al. [3] reported 27 %, Katz et al. [4] reported 30 %, Østerås et al. reported 0 % [8], Vermesan et al. reported 17 % [15], and Sihvonen et al [6] reported 7 %. Gauffin [7] found that 16 patients (21 %) crossed over from the non-surgery group to receive an operation after 3 months.

[11] Rimington T, Mallik K, Evans D, Mroczek K, Reider B. *A prospective study of the nonoperative treatment of degenerative meniscus tears*. Orthopedics. 2009 **Level of evidence IV.**

In this series twenty-six patients were followed for 37 months and evaluated clinically, radiographically, and with a standardized, validated Modified Lysholm Knee Scoring System (MLKS) and Standardized Activities of Daily Living Scale of the Knee (SADL) questionnaires. Patients were initially treated with 4 weeks of non-steroidal anti-inflammatory drugs. After four weeks, they were offered arthroscopic partial meniscectomy or continued non-operative treatment. Forty-six percent of patients (12 of 26) declined operative treatment. The mean length of time between enrollment and surgery was 3 months (range, 1-13 months). Both groups improved significantly over baseline ($P < .05$). The initial and final SADL and initial MLKS scores of the two groups were not significantly different

($P > .05$). The final MLKS score of the operative treatment group was significantly greater than the non-operative group ($P = .04$). Both the non-operative and operative treatment groups improved significantly at 3-year follow-up.

[14] Vermesan D, Prejbeanu R, Laitin S, Damian G, Deleanu B, Abbinante A, Flace P, Cagiano R. *Arthroscopic debridement compared to intra-articular steroids in treating degenerative medial meniscal tears*. Eur Rev Med Pharmacol Sci. 2013 **Level of evidence II**.

In this study Vermesan et al included 120 consecutive cases of non-traumatic symptomatic knees which had degenerative lesions of the medial compartment (cartilage and meniscus) on MRI's randomized to receive either intraarticular steroid injection or arthroscopic debridement. At one month there was significant improvement of the scores for all the examined cases. Also at one month, the arthroscopic group performed better in terms of symptom improvement. This was maintained for 79% of the knees in the arthroscopic group and 61% in the intraarticular steroid injection respectively, out of those available for follow up at one year. At one month, symptoms reappeared for 12 patients in the steroid group and 7 in the arthroscopy respectively. 10 patients cross-over from steroid group to surgery.

Q5) Is the concept of an unstable meniscus useful for indicating meniscectomy (locking, clicking, MRI flap, etc....)?

Steering group answer:

There are controversies regarding the definition and role of mechanical symptoms as an indication for arthroscopic partial meniscectomy (APM). The definition of “mechanical symptoms” remains unclear and further investigations are needed, as it may cover a wide range of symptoms with different severity and frequency. In a recent RCT [7], patients’ symptom history (i.e., mechanical symptoms or acute onset of symptoms) didn’t affect outcomes (but patients with joint locking more than 2 seconds more often than once a week were excluded). Pooled results [15] of all RCT’s reveal very limited added benefit of APM for degenerative meniscus regardless of preoperative symptoms (fixed locking knee or knee with recurrent catching symptoms excluded).

Grade A

A recent study [16] did not find any benefits over sham surgery to relieve knee catching or occasional locking. Grade A.

Indication for early APM depends on intensity, frequency of mechanical symptoms, and clear physical exam (fig 1).

Grade D

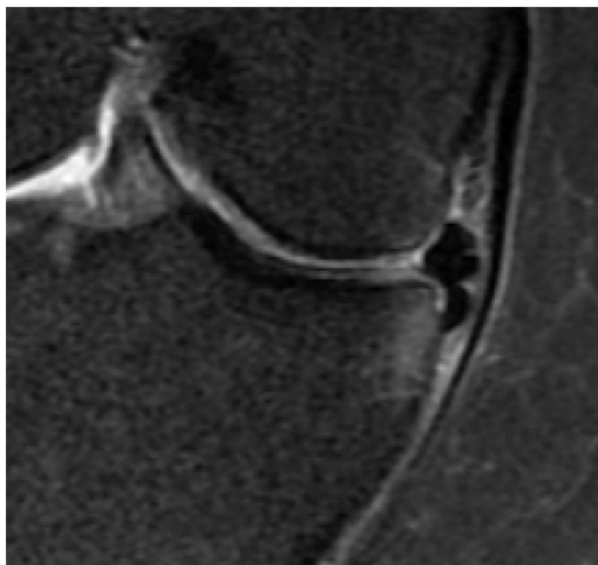


Figure 1: medial meniscus flap subluxated in the tibial gutter with bony impingement. This kind of lesion may be associated with significant mechanical symptoms.

Literature review:

Gauffin et al [7] published a single-blinded RCT including mild-aged (45-60 yr) patients with “meniscal symptoms” for at least three months **and “non arthritic” (Kellgren-Lawrence <2) knees**. Patients were excluded when they had a locked knee or joint locking for more than 2 seconds more often than once a week. After four weeks of functional treatment, patients were divided into two groups: **surgery (within four week after a physician’s appointment)** or **functional treatment (3 months)**. 150 patients were included in this interesting series, even if some clinical outcomes were different between the two groups during the baseline evaluation (KOOS Pain subscore), the authors concluded that **for these patients (“meniscal symptoms” / no OA) APM might result in better clinical results (KOOS/EuroQOL 5D/VAS) at 3 and 12 months**. However, the study was not able to identify a subgroup of patients that might benefit more from surgery; patient age, mechanical symptoms, or acute onset of symptoms didn’t affect the outcomes.

[15]Thorlund JB, Juhl CB, Roos EM, Lohmander LS.

Arthroscopic surgery for degenerative knee: systematic review and meta-analysis of benefits and harms. Br Med J. 2015 **Level I-II studies Meta-analysis.**

The authors identified nine trials assessing the benefits of knee arthroscopic surgery in middle aged and older patients with knee pain and degenerative knee disease. The main analysis, combining the primary endpoints of the individual trials from three to 24 months postoperatively, showed a small difference in favour of interventions including arthroscopic surgery compared with control treatments for pain (effect size 0.14, 95% confidence interval 0.03 to 0.26). **This difference corresponds to a benefit of 2.4 (95% confidence interval 0.4 to 4.3) mm on a 0-100 mm visual analogue scale.** When analysed over time of follow-up, interventions including arthroscopy showed a small benefit of 3-5 mm for pain at three and six months but not later up to 24 months. **No significant benefit in physical function was found** (effect size 0.09, -0.05 to 0.24). Nine studies reporting on harm were identified. Harm included symptomatic deep venous thrombosis (4.13 (95% confidence interval 1.78 to 9.60) events per 1000 procedures), pulmonary embolism, infection, and death.

The authors concluded that small inconsequential benefit seen from interventions that include arthroscopy for the degenerative knee was limited in time and absent at one to two years after surgery. Knee arthroscopy was associated with harm. Taken together, these findings do not support the practice of arthroscopic surgery for middle aged or older patients with knee pain with or without signs of OA.

This meta-analysis included Gauffin et al study [7] and such supports Grade A recommendation for patients suffering from a **painful, non-locked knee** secondary to a degenerative meniscus lesion.

[16] Sihvonen R, Englund M, Turkiewicz A, Järvinen TL; Finnish Degenerative Meniscal Lesion Study Group.

Mechanical Symptoms and Arthroscopic Partial Meniscectomy in Patients With Degenerative Meniscus Tear: A Secondary Analysis of a Randomized Trial. Ann Intern Med. 2016. **Level of evidence I.**

In their secondary analysis, Sihvonen et al, analyzed outcomes of APM vs Sham surgery focusing on patients with severe mechanical symptoms (knee catching and occasional locking). From their original series, 32 patients in the APM group and 37 in the sham surgery group reported catching or locking before surgery. Patients were evaluated using self-report

of mechanical symptoms and clinical scores before surgery and at 2, 6, and 12 months after surgery. They concluded that resection of a torn meniscus has no added benefit over sham surgery to relieve knee catching or occasional locking.

Q 6) What outcomes can be expected after arthroscopic partial meniscectomy (APM)?

Steering group answer:

1. Improvement of functional outcomes can be expected after APM. Grade A [3-6, 15-18]

2. Most of the RCTs found no difference in terms of clinical outcomes after surgery compared to non-operative treatment. Grade A. [3-6, 15, 16]

3. When Surgical treatment after non operative treatments failure, APM will result in similar but not superior results than successful non-operative treatment [3-7, 15, 17].

Grade A.

4. 3-6% of patients will require another surgical procedure in the year following APM.[3-6] Grade A.

5. Various predictive factors of poor results or treatment failures have been described in the current literature (increased BMI, lateral side, chondral damage, bone marrow oedema, meniscal extrusion (fig 2), total or subtotal meniscectomy . Grade C. [19-20]

The steering group wants to state that:

Those affirmations are concerned with RCT Per-Protocol analyses.

If the mid-term outcomes are similar, then the short-term outcomes (<12Months) might be better with APM than with non operative treatment [4-6].

The indication for early APM may also depend on the intensity and frequency of mechanical symptoms, as well as physical evaluation.

Grade D

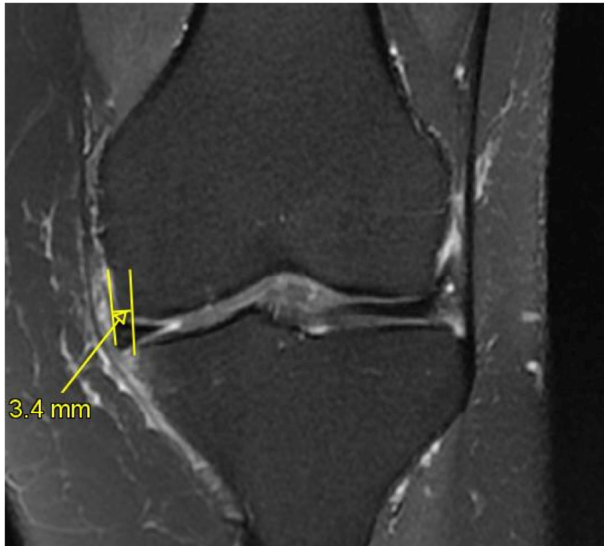


Figure 2: medial meniscus extrusion (>3mm) demonstrating early osteoarthritic stage
(MRI : coronal view ; T2 FS)

Literature review:

Clinical and radiological outcomes after meniscectomy.

Level I studies.

Four RCTs have compared APM with physical therapy in older (mean age ≥ 45 years) individuals with symptomatic knee OA [3–5,16], while one RCT compared APM with sham surgery in people with medial meniscal tears [Sihvonen 6]. The primary outcomes in these studies were clinical measures of pain and function, using validated instruments, including the Western Ontario and McMaster Universities Arthritic Index, the Knee Injury and Osteoarthritis Outcome Score, the Lysholm Knee Score, the Tegner activity level and visual analogue scales. In all RCTs, both the APM and physical therapy groups showed clinical improvements from baseline to follow-up, although superiority of APM compared with physical therapy could not be demonstrated at any time point. In the most recent RCT [Yim 5], no significant differences in terms of relief of knee pain, improved knee function or patient satisfaction between APM and strengthening exercises could be discerned over 2 years of follow-up. In the study by Herrlin and colleagues, one-third of the patients in the exercise group had persisting and disabling knee symptoms after exercise therapy, but improved to the same degree as the APM group when APM was then employed among people who had initially failed to respond to exercise [Herrlin 3]. Nevertheless, the group

who required eventual APM was ill-defined. Possibly their symptoms were of a major mechanical origin, whereby knee locking predominated, and such a select subgroup may therefore benefit from APM as first-line treatment.

No in-between-group differences existed for improvement in pain levels 12 months post procedure for both the APM and sham APM procedure groups in people with medial meniscal tears [Sihvonen 6].

Reoperation rate after APM patients in Level 1 studies.

<i>Study</i>	<i>Number of patients</i>	<i>Reoperation rate</i>
<i>Herrlin et al [3]</i>	49	6%
<i>Katz et al [4]</i>	156	3%
<i>Yim et al [5]</i>	50	Not reported Dissatisfaction rate 8%
<i>Sihvonen et al [6]</i>	70	3%

Level II-III-IV studies

[17]Biedert RM. *Treatment of intrasubstance meniscal lesions: a randomized prospective study of four different methods.* Knee Surg Sports TraumatolArthrosc. 2000 **Level of evidence II.**

This RCT examined people with a mean age of 30.4 years (range 16 to 50 years) with a symptomatic medial meniscal tear and randomized them to several treatment arms, which included conservative treatment (non-steroidal anti-inflammatory drugs and local physical therapy, n = 12) and APM (n = 11). At just over a 2- year follow-up, patients who had an APM demonstrated better outcomes than conservative therapies. Indeed all the patients had a near-normal IKDC score with APM, compared with 75% with conservative measures (P = 0.006). Such results may therefore support the use of APM among younger people with meniscal tears. However, this study was limited by the small number of patients completing the RCT (n = 23), and these results need to be corroborated in a larger RCT. It is also unclear whether the 25% of patients who did not normalize their IKDC score had specific symptoms, such as knee locking, and therefore represented a select subgroup of people who were unlikely to improve with conservative measures. It must be acknowledged that 75% of

patients still improved and were normal or nearly normal with regards to their IKDC scores in the non operative group, therefore avoiding APM.

[18]Khan M, Evaniew N, Bedi A, Ayeni OR, Bhandari M. *Arthroscopic surgery for degenerative tears of the meniscus: a systematic review and meta-analysis*. CMAJ.2014 **Level I-II studies Meta-analysis.**

In this meta-analysis, arthroscopic debridement resulted in a significant improvement in short-term function across 6 trials [4–6,8,13,14]involving a total of 805 patients (SMD 0.25, 95% CI 0.02 to 0.48) with moderate heterogeneity.

Arthroscopic treatment did not improve short-term pain across 3 trials [5,6,8,14,]that reported short-term visual analogue scores from 355 patients (mean difference [MD] 0.20, 95% CI – 0.67 to 0.26) with low heterogeneity ($p = 0.36$, $I^2 = 6\%$). Similarly, long-term pain after arthroscopic debridement across 3 trials [3,5,6] involving 344 patients did not show a significant improvement in pain scores (MD –0.06, 95% CI –0.28 to 0.15) and had low heterogeneity ($p = 0.75$, $I^2 = 0\%$).

[19] Salata MJ, Gibbs AE, Sekiya JK. *A systematic review of clinical outcomes in patients undergoing meniscectomy*. Am J Sports Med. 2010 **Level I-II studies .Meta-analysis.**

In the meta-analysis Salata et al, analyzed post operative clinical or radiographic outcomes of patients undergoing total or partial meniscectomy. They included 4 randomized controlled trials, 2 prospective cohorts, and 23 retrospective studies. Pooled results of these studies demonstrated that total meniscectomy or removal of the peripheral meniscal rim, lateral meniscectomy, degenerative meniscal tears, presence of chondral damage, presence of hand osteoarthritis suggestive of a genetic predisposition, and increased body mass index were independent risk factors of poor clinical and radiological outcomes after arthroscopic meniscectomy.

[20]Kijowski R, Woods MA, McGuine TA, Wilson JJ, Graf BK, De Smet AA. *Arthroscopic partial meniscectomy: MR imaging for prediction of outcome in middle-aged and elderly patients*. Radiology. 2011 **Level of evidence IV.**

In their prospective radiological series, Kijowski et al evaluated predictive factors of APM outcomes for 53 men and 47 women (average ages, 54.5 and 56.6 years, respectively). Patients underwent knee MR imaging before APM; clinical symptoms were evaluated preoperatively and 1 year postoperatively with the International Knee Documentation



Committee (IKDC) questionnaire. Poorer clinical outcome after APM was associated with greater severity of cartilage loss and bone marrow oedema in the same compartment as the meniscal tear, greater severity of meniscal extrusion, greater overall severity of joint degeneration, a meniscal root tear, and a longer meniscal tear at preoperative MR imaging.

Q7) What is the rate of surgical complications after meniscus resection?

Steering group answer:

The rate of surgical complication is low (0.27-2.8%). Grade A.

After APM, the rate of complications is dependent on side: i.e. a lateral meniscectomy is associated with a higher rate of complications than a medial one.

Grade A

Literature review:

Complications.

Two RCTs reported on adverse events: Sihvonen et al. [6] reported 1 infection in the group undergoing arthroscopic meniscal debridement as compared with a sham procedure. Katz and colleagues [4] reported 3 serious adverse events in the group undergoing arthroscopic meniscal debridement and 2 in the group undergoing physical therapy.

In their recent meta-analysis Thorlund et al [15] identified that deep venous thrombosis was the most frequently reported symptomatic adverse event associated with arthroscopic meniscectomy, with 4.13 (95% confidence interval 1.78 to 9.60) events per 1000 procedures, followed by infection, pulmonary embolism, and death. These conclusions should be assessed with caution, depending on treatment customs according to each country (for instance: anticoagulation or not)

[21]Hagino T, Ochiai S, Watanabe Y, Senga S, Wako M, Ando T, Sato E, Haro H.

Complications after arthroscopic knee surgery. Arch Orthop Trauma Surg 2014. Level of evidence IV.

Hagino et al, a series investigating on complication after arthroscopic knee surgery reported a low rate of intra and postoperative complications (7 in 2,623 cases: 0.27 %).

[22]Salzler MJ, Lin A, Miller CD, Herold S, Irrgang JJ, Harner CD.

Complications after arthroscopic knee surgery. Am J Sports Med 2014. **Level of evidence IV.**

Salzler et al, found a 2.8% complication rate after arthroscopic meniscectomy in the American Board of Orthopaedic Surgery database (92,565 cases) and concluded that Knee arthroscopy was not a benign procedure.

Q8) What is the risk of osteoarthritis after meniscus resection?

Steering group answer:

- 1. Patients treated with APM for degenerative meniscus lesion present a higher risk for symptomatic knee osteoarthritis compared to patients with normal knee (healthy subjects). Risk of OA is higher on the lateral side. Grade C***
- 2. Patients with a total meniscectomy (removal of the peripheral rim) present a higher risk for symptomatic knee osteoarthritis compared to patients with partial meniscectomy. Grade C***
- 3. Cartilage damage or Bone Oedema prior to APM is a major factor of failure. Grade C.***
- 4. Meniscus extrusion is a predictive factor of local osteonecrosis after APM. Grade C***

Literature review:

[23] Chatain F, Robinson AH, Adeleine P, Chambat P, Neyret P. The natural history of the knee following arthroscopic medial meniscectomy. *Knee Surg Sports Traumatol Arthrosc.* 2001 **Level of evidence IV.**

The authors examined the natural history of arthroscopic medial meniscectomy in 317 knees with an isolated medial meniscectomy and no history of previous surgery. The patients were reviewed clinically and radiologically after a mean of 11.5 years (range 10-15). The knee was considered "normal" or "nearly normal" by 91% of patients. In 218 patients the contralateral knee was asymptomatic without history of operation or significant injury and could be used as control for comparison. Radiological analysis showed 22.4% greater prevalence of joint space narrowing in the operated compared to the control knee. The factors predisposing to a poor radiological result were age above 35 years, the presence of medial compartment cartilage degeneration at the time of the first arthroscopy, resection of the posterior one-third of the meniscus, and meniscal rim resection.

[24]Hulet C, Menetrey J, Beaufils P, Chambat P, Djian P, Hardy P, Potel JF, Servien E, Seil

R; French Arthroscopic Society (SFA). *Clinical and radiographic results of arthroscopic partial lateral meniscectomies in stable knees with a minimum follow up of 20 years.*

Knee Surg Sports Traumatol Arthrosc 2015 **Level of evidence IV.**

In their retrospective multicentric study, Hulet et al evaluated the long-term effects of lateral meniscectomy to identify risk factor of osteoarthritis (OA). Eighty-nine arthroscopic partial lateral meniscectomies in stable knees with a mean follow-up of 22 ± 3 years were included. The authors evaluated age, sex, body mass index (BMI), physical activity, alignment, the types of meniscus lesions, the extent of meniscal resections and the initially associated cartilage lesions, as potential risk factors of OA. The prevalence of OA was 56% in the affected knee and the difference of prevalence between the operated and healthy knees was 44%. Predictors of OA were an age superior to 38 years at the time of surgery, obesity (BMI >30), and valgus malalignment as well as the presence of cartilage and degenerative meniscus lesions at the time of surgery.

[25]Englund M, Roos EM, Lohmander LS. *Impact of type of meniscal tear on radiographic and symptomatic knee osteoarthritis: a sixteen-year follow up of meniscectomy with matched controls.* Arthritis Rheum. 2003 **Level of evidence IV.**

In this cohort study that compared outcomes of people with intact anterior cruciate ligaments (ACLs) who had undergone APM for an isolated meniscal tear, it was found that there was a high risk of radiographic and symptomatic OA at 16-year follow-up. In subgroup analyses, outcomes were worse in those with degenerative tears and extensive resection. Such findings prompted the authors to conclude that degenerative meniscal tears may be associated with incipient OA.

[26]Englund M, Lohmander LS. *Risk factors for symptomatic knee osteoarthritis fifteen to twenty-two years after meniscectomy.* Arthritis Rheum. 2004 **Level I-II studies Meta-analysis.**

Englund et al (26) examined the risk of developing knee OA 15-22 years following either partial, subtotal or total meniscectomy and compared the risk against people who did not have any clinical suspicion of meniscal tear and no meniscectomy. This study found that partial meniscectomy was associated with less radiographic OA than was total meniscectomy. Nevertheless, symptomatic radiographic knee OA was more likely to occur in operated knees (27%) than in reference subjects' knees (10%) (relative risk = 2.6; 95% confidence interval = 1.3 to 6.1), i.e. pooled estimate regardless of the type of resection performed and type of meniscal tear).

Q9) Is there a place for arthroscopic lavage (or lavage-debridement: arthroscopic procedure including degenerative (meniscal/chondral) and/or synovial tissue debridement?) for OA knees?

Steering group answer:

There is no place for arthroscopic lavage (or lavage debridement) for painful knees with osteoarthritis (K/L \geq 2). RCT's [1, 2] have showed that debridement/lavage has little, if any, effect on patients short-terms reported outcomes, satisfaction, or pain compared to non-operative treatment. Grade A

Debridement might be indicated for young patients suffering from considerable mechanical symptoms. Grade D

Literature review:

Study	Inclusion criteria (arthritis)	Conclusion
<i>Moseley study</i> [1]	KL \leq 4	Debridement = Sham
<i>Kirkley study</i> [2]	KL 2-4	Debridement = PT

Q 10) When should arthroscopic partial meniscectomy (APM) be proposed?

Steering group answer:

1. *Surgery shouldn't be proposed as a FIRST line of treatment of degenerative meniscus lesions [15]. Grade A*
2. *After 3 months with non-operative treatment and persistent pain /mechanical symptoms (3 Months corresponds to the mean period between non operative treatment and conversion to APM in RCT(s), for a degenerative meniscus lesion with normal x-rays/ abnormal MRI (grade III meniscus lesion), APM may be proposed . The patient has to be informed about chances and risks of either method. Grade B*

3. *Surgery can be proposed earlier for patients presenting considerable mechanical symptoms (7). The patient has to be informed of chances and risks of either methods. Grade D*

However, the steering group wants to state that mechanical symptoms cannot be clearly defined according to the current literature.

4. *No arthroscopic surgery should be proposed for a degenerative meniscus lesion with advanced OA on weight bearing radiographs [1,2]. Grade A*

Exception should be discussed for young patient with considerable symptoms.

Literature review:

<i>Study</i>	<i>Beginning of Symptoms to Inclusion</i>	<i>Inclusion to conversion (APM)</i>
<i>Sihvonens et al [6]</i>	<i>> 3 months</i>	<i>8 months</i>
<i>Stensrud et al [9]</i>	<i>> 2 months</i>	<i>??</i>
<i>Herrlin et al [3]</i>	<i>> 2 months</i>	<i>??</i>
<i>Yim et al [5]</i>	<i>> 1 month</i>	<i>??</i>
<i>Katz et al [4]</i>	<i>> 1 month</i>	<i>< 6 months (40 % < 3 months 40 % > 3months 20 % > 6months)</i>
<i>Gauffin et al [7]</i>	<i>7 months</i>	<i>> 3 months</i>

Algorithm of management

Main evidence concerning degenerative meniscus treatment timing:

1. *Because no study defines the optimal timing between the onset of symptoms, the beginning of non-operative treatment and the surgical decision following non-operative treatments failure, three months after the onset of the symptoms should be considered as a reasonable time before the APM decision. This time corresponds to the mean period between non operative treatment and conversion to APM in RCT(s). Grade A*

Literature review:

<i>Study</i>	<i>Duration before orthopaedic's evaluation</i>

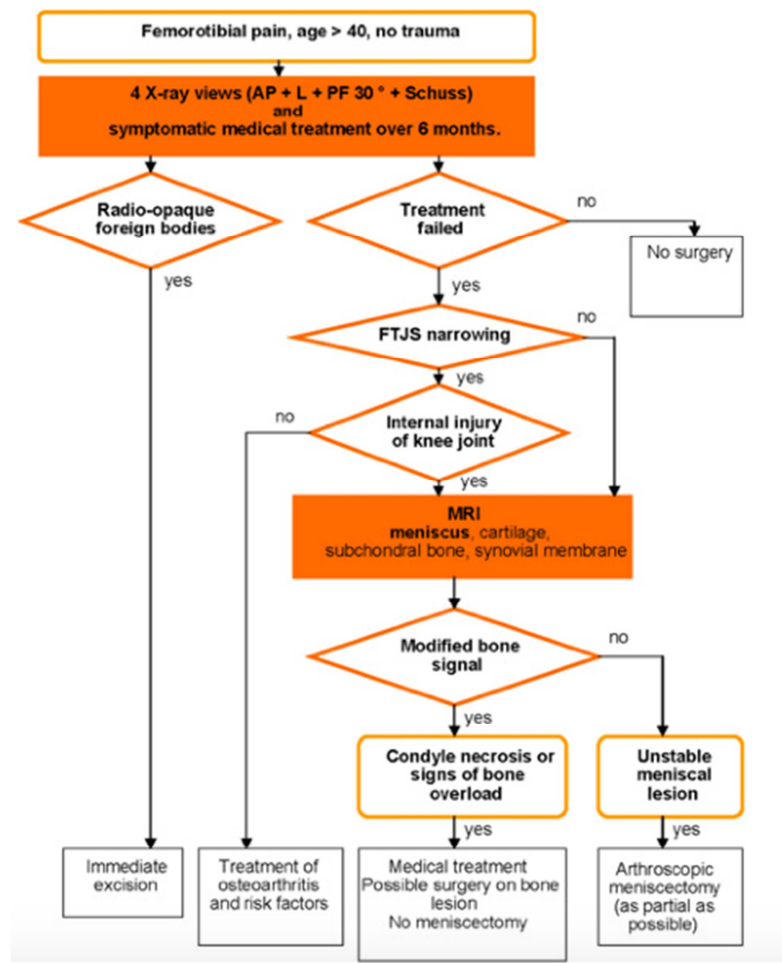
<i>Stensrud et al [9]</i>	2 mo
<i>Herrlin et al [3]</i>	2-6mo
<i>Yim et al [5]</i>	8 mo
<i>Katz, et al [4]</i>	1 mo
<i>Gauffin et al [7]</i>	3 mo

2. *Three to 6 months after the onset of symptoms should elapse before any surgery proposal for a patient suffering from non-locked, non-arthritic knee pain due to a degenerative meniscus lesion. Grade A*

Study	Minimal duration of non operative treatment before APM.
<i>Østerås et al [8]</i>	12-16 weeks
<i>Stensrud et al [9]</i>	12 weeks
<i>Herrlin et al [3]</i>	8 weeks
<i>Yim et al [5]</i>	8 weeks
<i>Neogi et al [10]</i>	12 weeks + home exercises
<i>Rimington et al [11]</i>	4 weeks AINS +/- rehab long term

An earlier surgical indication can be considered in the case of considerable mechanical symptoms (such as lack of range of motion; daily joint catching; and joint locking for more than 2 seconds over at least one week). Grade D

Which algorithm has been proposed in the literature?



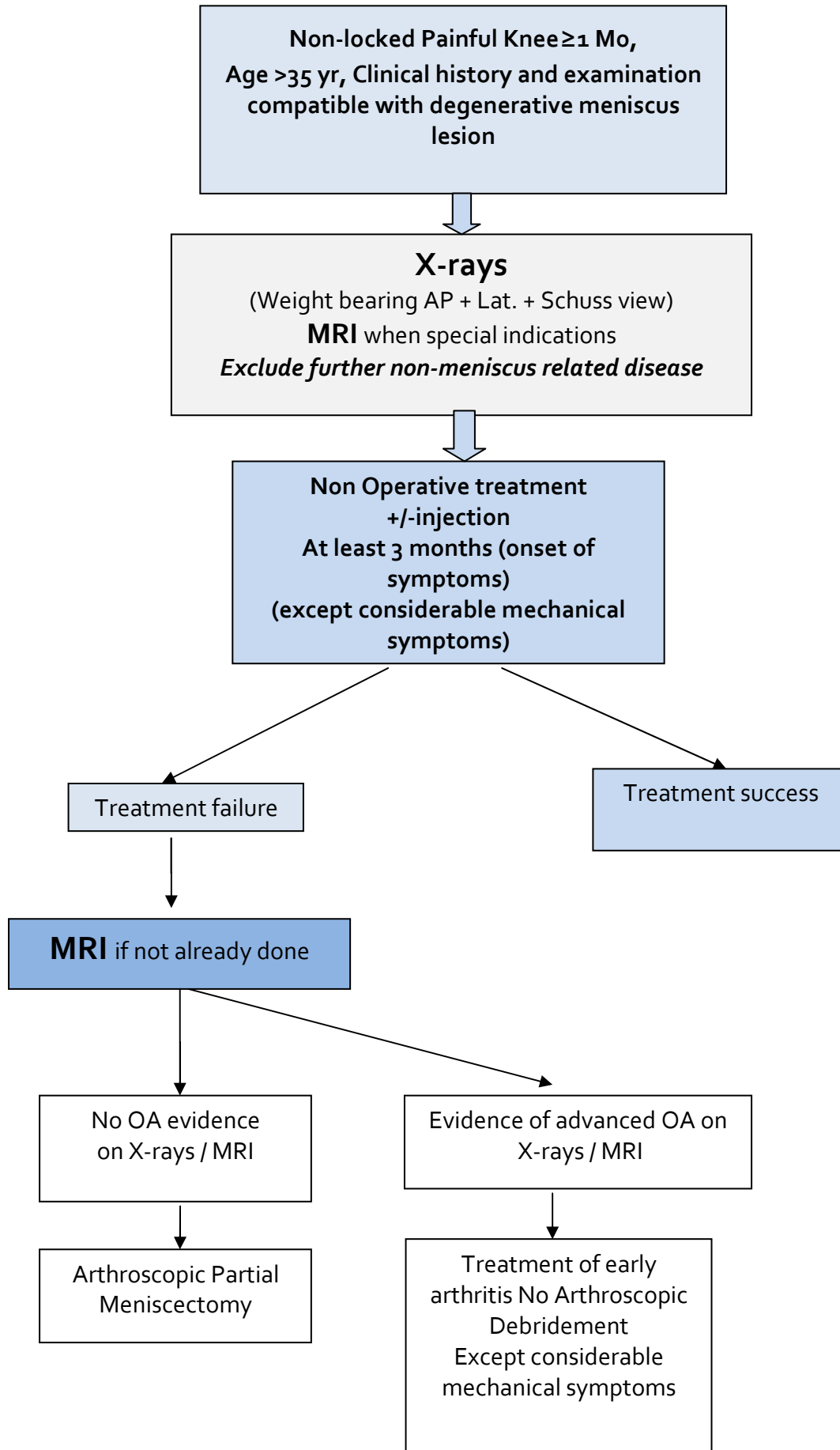
[27]Beaufils P, Hulet C, Dhénain M, Nizard R, Nourissat G, Pujol N. *Clinical practice guidelines for the management of meniscus lesions and isolated lesions of the anterior cruciate ligament of the knee in adults*. OrthopTraumatolSurg Res. 2009 **Level of Evidence 4**.

Beaufils et al [25]proposed in 2009 a clinical guideline concerning treatment of degenerative meniscus lesion. The reader should be aware that only two of the RCTs discussed above were published at the time of this publication, leading to substantial differences between our recommendation and theirs:

- Sihvonen et al [6] RCT defining minimal age at 35 years was published in 2013.
- RCTs on no-mild OA knee were published after 2013 and thus Beaufils et al divided their guidelines based on OA status [22].
- Most of RCTs on functional treatment vs arthroscopy for degenerative meniscus were published after 2010, allowing us to define a clear duration

ESSKA Meniscus Consensus algorithm

Degenerative Meniscus Lesion



References:

1. Moseley JB, O'Malley K, Petersen NJ, Menke TJ, Brody BA, Kuykendall DH, Hollingsworth JC, Ashton CM, Wray NP. A controlled trial of arthroscopic surgery for osteoarthritis of the knee. *N Engl J Med.* 2002 11;347:81–8.
2. Kirkley A, Birmingham TB, Litchfield RB, Giffin JR, Willits KR, Wong CJ, Feagan BG, Donner A, Griffin SH, D'Ascanio LM, Pope JE, Fowler PJ. A randomized trial of arthroscopic surgery for osteoarthritis of the knee. *N Engl J Med.* 2008 11;359:1097–107.
3. Herrlin SV, Wange PO, Lapidus G, Hållander M, Werner S, Weidenhielm L. Is arthroscopic surgery beneficial in treating non-traumatic, degenerative medial meniscal tears? A five year follow-up. *Knee Surg Sports TraumatolArthrosc.* 2013 ;21:358–64.
4. Katz JN, Brophy RH, Chaisson CE, et al Surgery versus physical therapy for a meniscal tear and osteoarthritis. *N Engl J Med.* 2013 ;368:1675–84.
5. Yim J-H, Seon J-K, Song E-K, Choi J-I, Kim M-C, Lee K-B, Seo H-Y. A comparative study of meniscectomy and nonoperative treatment for degenerative horizontal tears of the medial meniscus. *Am J Sports Med.* 2013;41:1565–70.
6. Sihvonen R, Paavola M, Malmivaara A, Itälä A, Joukainen A, Nurmi H, Kalske J, Järvinen TLN, Finnish Degenerative Meniscal Lesion Study (FIDELITY) Group. Arthroscopic partial meniscectomy versus sham surgery for a degenerative meniscal tear. *N Engl J Med.* 2013 ;369:2515–2524.
7. Gauffin H, Tagesson S, Meunier A, Magnusson H, Kvist J. Knee arthroscopic surgery is beneficial to middle-aged patients with meniscal symptoms: a prospective, randomised, single-blinded study. *OsteoarthrCartilOsteoarthr Res Soc.* 2014 ;22:1808–16.
8. Osteras H, Osteras B, Torstensen TA. Medical Exercise Therapy is Effective After



- Arthroscopic Surgery of Degenerative Meniscus of the Knee: A Randomized Controlled Trial. *J Clin Med Res.* 2012 ;4:378–84.
9. Stensrud S, Roos EM, Risberg MA. A 12-week exercise therapy program in middle-aged patients with degenerative meniscus tears: a case series with 1-year follow-up. *J Orthop Sports PhysTher.* 2012 ;42:919–31.
 10. Neogi DS, Kumar A, Rijal L, Yadav CS, Jaiman A, Nag HL. Role of nonoperative treatment in managing degenerative tears of the medial meniscus posterior root. *J OrthopTraumatol.* 2013 ;14:193–9.
 11. Rimington T, Mallik K, Evans D, Mroczek K, Reider B. A prospective study of the nonoperative treatment of degenerative meniscus tears. *Orthopedics.* 2009 ;32; doi: 10.3928/01477447-20090624-06.
 12. Dorfmann H, Labaune D. Knee arthroscopy: role of the arthroscopist in prescription. Apropos of a 3-year survey. *Rev ChirOrthopReparatriceAppar Mot.* 1990;76:468-72.
 13. Hede A, Hempel-Poulsen S, Jensen JS. Symptoms and level of sports activity in patients awaiting arthroscopy for meniscal lesions of the knee. *J Bone Joint Surg Am.* 1990;72:550-2.
 14. Vermesan D, Prejbeanu R, Laitin S, Damian G, Deleanu B, Abbinante A, Flace P, Cagianò R. Arthroscopic debridement compared to intra-articular steroids in treating degenerative medial meniscal tears. *Eur Rev Med Pharmacol Sci.* 2013;17:3192–6.
 15. Thorlund JB, Juhl CB, Roos EM, Lohmander LS. Arthroscopic surgery for degenerative knee: systematic review and meta-analysis of benefits and harms. *Br Med J.* 2015 ; 49: 1229-35
 16. Sihvonen R, Englund M, Turkiewicz A, Järvinen TL; FinnishDegenerativeMeniscalLesionStudy Group. MechanicalSymptoms and Arthroscopic Partial Menisectomy in Patients WithDegenerativeMeniscus Tear: A



Secondary Analysis of a Randomized Trial. *Ann Intern Med.* 2016 Feb 9. doi:
10.7326/M15-0899

17. Biedert RM. Treatment of intrasubstance meniscal lesions: a randomized prospective study of four different methods. *Knee Surg Sports Traumatol Arthrosc.* 2000;8:104–108.
18. Khan M, Evaniew N, Bedi A, Ayeni OR, Bhandari M. Arthroscopic surgery for degenerative tears of the meniscus: a systematic review and meta-analysis. *CMAJ.* 2014; 186:1057-64
19. Kijowski R, Woods MA, McGuine TA, Wilson JJ, Graf BK, De Smet AA. Arthroscopic partial meniscectomy: MR imaging for prediction of outcome in middle-aged and elderly patients. *Radiology.* 2011;259:203-12.
20. Salata MJ, Gibbs AE, Sekiya JK. A systematic review of clinical outcomes in patients undergoing meniscectomy. *Am J Sports Med.* 2010 ;38:1907-16.
21. Hagino T, Ochiai S, Watanabe Y, Senga S, Wako M, Ando T, Sato E, Haro H. Complications after arthroscopic knee surgery. *Arch Orthop Trauma Surg.* 2014 ;134:1561-4.
22. Salzler MJ, Lin A, Miller CD, Herold S, Irrgang JJ, Harner CD. Complications after arthroscopic knee surgery. *Am J Sports Med.* 2014 ;42:292-6
23. Chatain F, Robinson AH, Adeleine P, Chambat P, Neyret P. The natural history of the knee following arthroscopic medial meniscectomy. *Knee Surg Sports Traumatol Arthrosc.* 2001;9:15–18.
24. Hulet C, Menetrey J, Beaufils P, Chambat P, Djian P, Hardy P, Potel JF, Servien E, Seil R; French Arthroscopic Society (SFA). Clinical and radiographic results of arthroscopic partial lateral meniscectomies in stable knees with a minimum follow up of 20 years. *Knee Surg Sports Traumatol Arthrosc.* 2015 ;23:225-31



25. Englund M, Roos EM, Lohmander LS. Impact of type of meniscal tear on radiographic and symptomatic knee osteoarthritis: a sixteen-year followup of meniscectomy with matched controls. *Arthritis Rheum.* 2003 ;48:2178–87.
26. Englund M, Lohmander LS. Risk factors for symptomatic knee osteoarthritis fifteen to twenty-two years after meniscectomy. *Arthritis Rheum.* 2004 ;50:2811–9.
27. Beaufils P, Hulet C, Dhénain M, Nizard R, Nourissat G, Pujol N. Clinical practice guidelines for the management of meniscal lesions and isolated lesions of the anterior cruciate ligament of the knee in adults. *OrthopTraumatolSurg Res.* 2009 ;95:437–42.

Appendix

This appendix describes non-operative treatment for the conservative treatment of degenerative meniscus lesions.

To summarize, there is a trend that physical therapy should be attempted as a first line before any other treatment. The length of a physical therapy program should be a minimum of 3-6 months.

The main goals of an exercise program are to control the pain and swelling, restore the range of motion (ROM), restore or maintain isolated muscle function, and optimize lower extremity neuromuscular coordination and muscle strength.

The program can be supervised by an experienced physical therapist initially to assure correct performance of the exercise, guide progression of the program and monitor adverse effects. The physical therapy program is divided into 3 phases. The patient has to achieve certain clinical milestones before progressing to the next phase.

In phase 1, reduction of pain and swelling is imperative for reducing arthrogenic muscle inhibition (AMI). AMI is a result of reflex activity after injury which leads to the inability to completely contract a muscle. Blocking or modifying the sensory signals responsible for initiating the inhibitory process or by activating the inhibited motor neurons directly can reduce AMI. Neuromuscular electrical stimulation (NMES) appears to be a promising intervention to use after ACL reconstruction to reduce AMI.

Initially, pain and swelling can be reduced by frequent application of ice (every two hours for 30 minutes) and activity reduction. In addition, frequent (high repetitions) low-resistance active and passive movements (e.g. pendulum motions) within the pain free ROM of the knee enhance the nutrition of the joint cartilage and thereby stimulate joint recovery.

The exercises, progression (*) frequency, supervision/nu supervision listed in tables below is derived from the RCT's. The program is both time and criterion based however with an emphasis on criteria.

(*) Stensrud: best physiological rationale for training progression whilst monitoring adverse effects.

phase 1	acute phase
appointments	<ul style="list-style-type: none"> • 3 training sessions per week: 1 with supervision, 2 non-supervised training sessions
rehabilitation goals	<ul style="list-style-type: none"> • Restore normal gait • Restore normal knee extension • Eliminate/reduce swelling • Restore quadriceps control
guidelines	<ul style="list-style-type: none"> • pain < 5 during/after exercise • pain should subside < 12 hours • no increase swelling (Stroke test/REF)
suggested exercises	<ul style="list-style-type: none"> • Knee extension on a bolster • Prone hangs • Supine wall slides, heel slides, knee flexion off the edge of the table • Quadriceps sets Straight leg raises 4 way leg lifts on for balance and hip strength • Abdominal isometrics • EMG feedback
cardiovascular exercise	<ul style="list-style-type: none"> • easy cycling on stationary bike
progression criteria	<p>Patient must meet 3 of the 4 criteria:</p> <ul style="list-style-type: none"> • No to minimal effusion (Stroke 0-1) • Knee A/PROM ≥ 115 degrees • Pain-free gait without crutches • Knee Pain $\leq 4/10$ • Muscle Strength $\geq 3/5$

Phase 2

Once the patient has regained good control of the muscles surrounding the knee, muscle strengthening exercises can be initiated. A combination of open kinetic chain (OKC) and closed kinetic chain (CKC) exercises can be used to improve upper leg muscle strength, but

the latter become more important with time because they are more functional for the lower limb.

Progression of exercises is based on the tolerance of the patient and monitoring of adverse effects like swelling after exercise as listed in the table. The intensity of the exercises has to be modified so that they can be performed within the pain limits.

phase 2	
appointments	<ul style="list-style-type: none"> • 1 time per week, 2 unsupervised training sessions
rehabilitation goals	<ul style="list-style-type: none"> • Single leg stand control • Good control and minimal/no pain with functional movements, including step up/down, squat, partial lunge (between 0° and 60° of knee flexion)
guidelines	<ul style="list-style-type: none"> • Pain < 3 during/after exercise • Pain should subside < 12 hours • Avoid post-activity swelling (Stroke test)
suggested exercises	<ul style="list-style-type: none"> • Commence neuromuscular control exercises beginning with low velocity, single plane activities • Non-impact balance and proprioceptive drills • Stationary bike • Start running drills • Hip and core strengthening • Quadriceps strengthening
cardiovascular exercise	<ul style="list-style-type: none"> • Prepare for sport or work specific energy demands

phase 2	
progression criteria	<ul style="list-style-type: none"> • Patient must meet 4 of the 5 criteria: • Knee A/PROM $0 \geq 125$ degrees • Minimal effusion • Knee Pain $\leq 2/10$ • Muscle Strength $\geq 4/5$ • Single leg balance greater than 15 seconds • Ability to carry out functional movements without unloading affected (injured) leg or pain, while demonstrating good control

Phase 3

The final phase of the exercise program is marked by sport-specific exercises

phase 3	Return to activity phase
appointments	<ul style="list-style-type: none"> • 1 time per week, 2 unsupervised training sessions
rehabilitation goals	<ul style="list-style-type: none"> • Good control and no pain with sport and work specific movements, including impact
guidelines	<ul style="list-style-type: none"> • Pain < 2 during/after exercise • Pain should subside < 12 hours • Avoid post-activity swelling (Stroke test)
suggested exercises	<ul style="list-style-type: none"> • Commence neuromuscular control exercises higher velocity, multi-plane activities • Strength and control drills related to sport specific movements • Sport/work specific balance • Hip and core strengthening
cardiovascular exercise	<ul style="list-style-type: none"> • Replicate sport or work specific energy demands based on e.g. %HRmax
progression criteria	<ul style="list-style-type: none"> • Dynamic neuromuscular control with multi-plane activities without pain or swelling



We emphasize the use of an individualized programme based on the patient's work or sports related demands. Currently, the main clinical challenge for the conservative management of patients with degenerative meniscal tears and knee pain is the lack of evidence in regard of what constitutes the best conservative treatment.