



Hip and Groin Pain in Physically Active Adults A Formal ESSKA-EHPA-ESMA Consensus

Introduction

Hip and groin pain are common in young and middle-aged active individuals and account for up to 10% of consultations in sports medicine. Pain-related limitations can result in significant functional losses or, in certain cases, cessation of an athletic career. The complex anatomy of the groin region has made diagnostic processes and treatment challenging. However, the growth of hip preservation as an orthopaedic subspecialty has seen a surge in recent years, with more procedures being performed and more surgeons, physiotherapists, sports medicine doctors and radiologists pursuing a career in this field. Hip preservation aims to prevent or delay the onset of degenerative changes in the hip, addressing both intra-articular and periarticular causes of hip pain in nonarthritic patients and consequently the procedures are mostly performed on active, young patients. The treatment options range from conservative treatments, e.g., active physical training, manual muscle manipulation and shockwaves, to surgical interventions, such as laparoscopic hernia surgery, tenotomies or hip arthroscopies.

Why a Consensus?

However, despite this growth, the terminology used to describe the diagnosis of hip and groin pain has been inconsistently used, resulting in the adoption of heterogeneous terms such as groin pain, athletic pubalgia, osteitis pubis, core muscles and sports hernia. A previous study revealed that 33 different terms were used to describe the diagnosis of groin pain in a literature review that included 72 studies. A previous Delphi study of experts also found that they used very heterogeneous terms to describe the diagnosis when presented with the same clinical cases. Over the past decade, several consensus statements have introduced classification systems and suggested nomenclature for hip joint and groin pain which have further confused the issue and universal adoption has been poor.

The aim of the ESSKA EHPA-ESMA Consensus, therefore, was to build a foundation for more precise communication specifically in terms of terminology, clinical examination, and radiological investigations that one would request when presented with a young active adult with hip or groin pain.

Goals of the consensus: Terminology/clinical examination/imaging of an active adult with hip and groin pain

Exclusion criteria: children and adolescents / treatment

Definitions/ abbreviations

FAI – Femoroacetabular Impingement

OA – Osteoarthritis

Methodology

The methodology employed has been so-called “Formal Consensus” and adopted by the European Society of Sports Medicine, Knee surgery and Arthroscopy (ESSKA). This is a modified Delphi methodology that is robust, clear, and rigorous based on an iterative evaluation by three groups of experts (ref Beaufils et al). The ultimate goal of this methodology is to provide a reference frame, rather than a strict guideline, on both the available literature and a balanced expert opinion. This reference frame seeks to be clinically helpful; that is, to help the daily practitioner in their clinical decisions.

Five groups of experts (hip surgeons, sports medicine doctors, hernia surgeons, radiologists, and physiotherapists) from 22 countries were involved: Three different groups were set up according to the ESSKA formal process: the Steering group chaired by two chairpersons and assisted by the ESSKA consensus projects advisor, the rating group, and the peer-review group. The steering group was formed by a question group, and a literature group. The whole steering group defined the topic; the question group proposed the list of questions, and the literature group did the literature search independently. Peer review for geographical adaptability for the final consensus was obtained from 22 experts based in 12 countries.

Three databases were used: Google Scholar, PubMed and ScienceDirect. Articles were included if they were written in English and were specifically conducted to investigate aspects related to the topic of the consensus. Review articles, case reports, short anecdotal case series, expert opinions or basic science articles were excluded. Duplicates were excluded and the title and abstracts were then checked for suitability. Those articles that were found related to the consensus were full text scrutinized and a final list of articles generated.

The entire steering group worked then on elaborating specific statements that represented specific answers to the 11 questions. Each statement was discussed among all members of the steering group through a series of numerous consecutive meetings.

Each statement was followed by a grade of recommendation, according to the following rules:

Grade A is defined as a high level of scientific support

Grade B as a scientific presumption

Grade C as a low level of scientific support,

Grade D as an expert opinion.

Grade of recommendations were provided during a specific meeting

Chairpersons:

Vikas Khanduja (UK), Per Hölmich (Denmark)

ESSKA Scientific Advisor:

Philippe Beaufils (France)

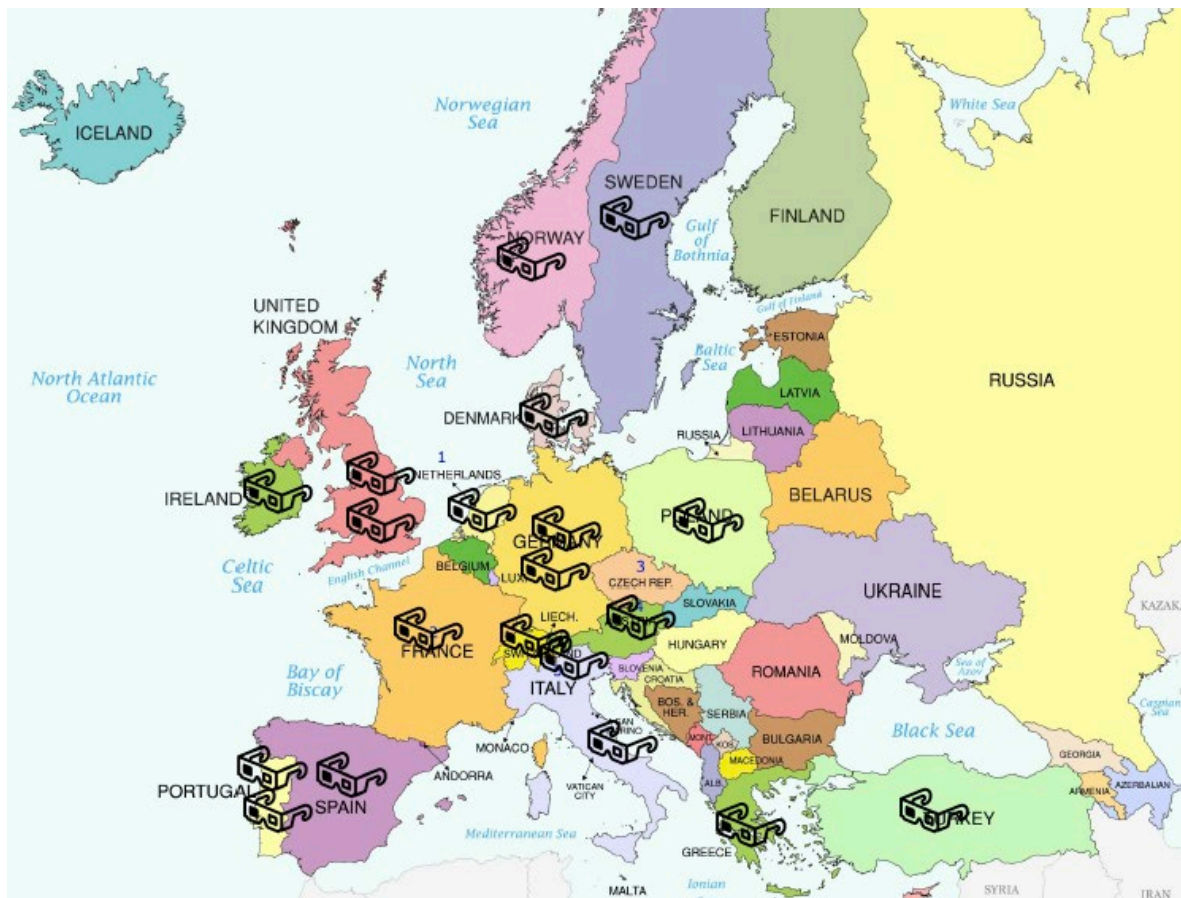Steering Group:

Name	Specialty	Country
Francesco Della Villa	Sports Medicine	Italy
Athanasios Papavasiliou	Orthopaedic Surgeon	Greece
Kristian Thorborg	Physiotherapist	Denmark
Lior Laver	Orthopaedic Surgeon	Israel
Oliver Marin Pena	Orthopaedic Surgeon	Spain
Femi Ayeni	Orthopaedic Surgeon	Canada
Theodora Papadopoulou	Sports Medicine Orthopaedic Surgeon	UK
Hannu Paajanen	Hernia Specialist	Finland
Ustun Aydingoz	Radiologist	Turkey
Adam Weir	Sports Medicine	Netherlands
Sufian Ahmed	Orthopaedic Surgeon	Germany
Gian Luigi Canata	Orthopaedic Surgeon	Italy

Rating Group:

Name	First name	County	comment
Agricola	Rintje	Netherlands	Orthopaedic surgeon ESMA
Mitrousias	Vasileios	Greece	Orthopaedic surgeon ESMA
Wörner	Tobias	Sweden	Physio ESMA
Person Krogh	Thoger	Denmark	Sports Physician ESMA
Andersen	Thor Einar	Norway	Sports Physician ESMA
Delahunt	Eamonn	Ireland	Physiotherapist ESMA
Reboul	Gilles	France	Abdominal surgeon - ESMA
Eirale	Cristiano	Italy	Sports Physician - ESMA
Wettstein	Michael	Switzerland	Orthopaedic Surgeon -EHPA
Schilders	Ernest	UK	Orthopaedic Surgeon
Mascarenhas	Vasco	Portugal	Radiologist
Sutter	Reto	Switzerland	Radiologist

Dijkstra	Paul	Aspetar	Sports Physician
Kocaoglu	Baris	Turkey	Orthopaedic Surgeon
Dantas	Pedro	Portugal	Orthopaedic Surgeon
Malviya	Ajay	UK	Orthopaedic Surgeon
Mazek	Jacek	Poland	Orthopaedic Surgeon
Reina	Nicholas	France	Orthopaedic Surgeon
Audenaert	Emmanuel	Belgium	Orthopaedic Surgeon
Bent	Lund	Denmark	Orthopaedic Surgeon
Vukovic	Zarko	Serbia	Abdominal surgeon - ESMA



Peer Review Group

Belgium (BKS), Czech Republic (CSSTA), Denmark (SAKS), Estonia (EASTS), France (SFTS), Georgia (GASSA), Germany (AGA), Hungary (MAT), Israël (ISKSA), Italy (SIAGASCOT), Norway (NAA), Poland (PTA), Slovenia (SSASST)

Acknowledgements:

Many thanks to the ESSKA Office and especially Anna Hansen Rak (Luxembourg) for her continuous and endless support of the consensus group.

Summary

I Terminology and Classification of hip and groin pain in physically active adults

CONCLUSIVE QUESTION

Which terminology and definitions for hip and groin pain in physically active adults are recommended?

II Clinical Examination

QUESTION 1: What clinical examination is relevant for determining the source of hip and groin pain?

QUESTION 2: Where do patients with groin pain with known intra- or extra-articular pathologies report their pain locations?

QUESTION 3: Is there an association of clinical examination tests of the hip and groin region and imaging findings?

QUESTION 4: Are clinical examination tests able to identify hip joint-related causes of groin pain in physically active adults?

CONCLUSIVE QUESTION: What clinical examination tests are recommended in physically active adults with hip and groin pain?

III Imaging

What is the interobserver and intraobserver reliability of imaging tests of the hip and groin?

What is the radiation dose and associated risk for radiography and CT scans?

QUESTION 1: Are imaging examinations of the hip joint able to differentiate between those with and without symptoms?

QUESTION 2: How are imaging examinations of the hip used to identify and measure cam and pincer morphology and acetabular coverage?

QUESTION 3: How are imaging examinations of the hip joint and groin region used to identify pathology?

QUESTION 4: Are imaging examinations of the hip and groin to give information about the prognosis?


QUESTION 5: Are diagnostic injections with local anaesthetic into the hip joint able to identify intraarticular pathology?

CONCLUSIVE QUESTIONS

Question 1: When is imaging indicated for physically active adults with hip and groin pain?

Question 2: In physically active adults with hip and groin pain, which imaging examinations are recommended as first line examinations? As second line examinations?

RATING PART STARTS ON THE NEXT PAGE



QUESTIONS AND STATEMENTS

I Terminology and Classification of hip and groin pain in physically active adults

CONCLUSIVE QUESTION

Which terminology and definitions for hip and groin pain in physically active adults are recommended?

Statement

Over the past decade, several consensus statements have introduced classification systems and suggested nomenclature for hip joint and groin pain which have further confused the issue and universal adoption has been poor. The aim of the ESSKA EHPA-ESMA Consensus, therefore, is to build a foundation for more precise communication specifically in terms of terminology, clinical examination, and radiological investigations that one would request when presented with a physically active adult with hip and groin pain.

Always consider the mechanism of injury, history, and pain pattern along with the clinical findings. It is important to note that the described clinical entities are not mutually exclusive, and multiple entities often co-exist.

Groin is defined as the junctional area between the torso and the anterior and medial thigh.

A clinical entity is used to identify a group of possible diagnoses, all related to a certain anatomical structure and connected by symptoms and specific clinical tests.

The terms adductor, iliopsoas, inguinal, pubic, and hip-joint related groin pain pathology should be used to describe the diagnosis of the common clinical entities of groin pain.

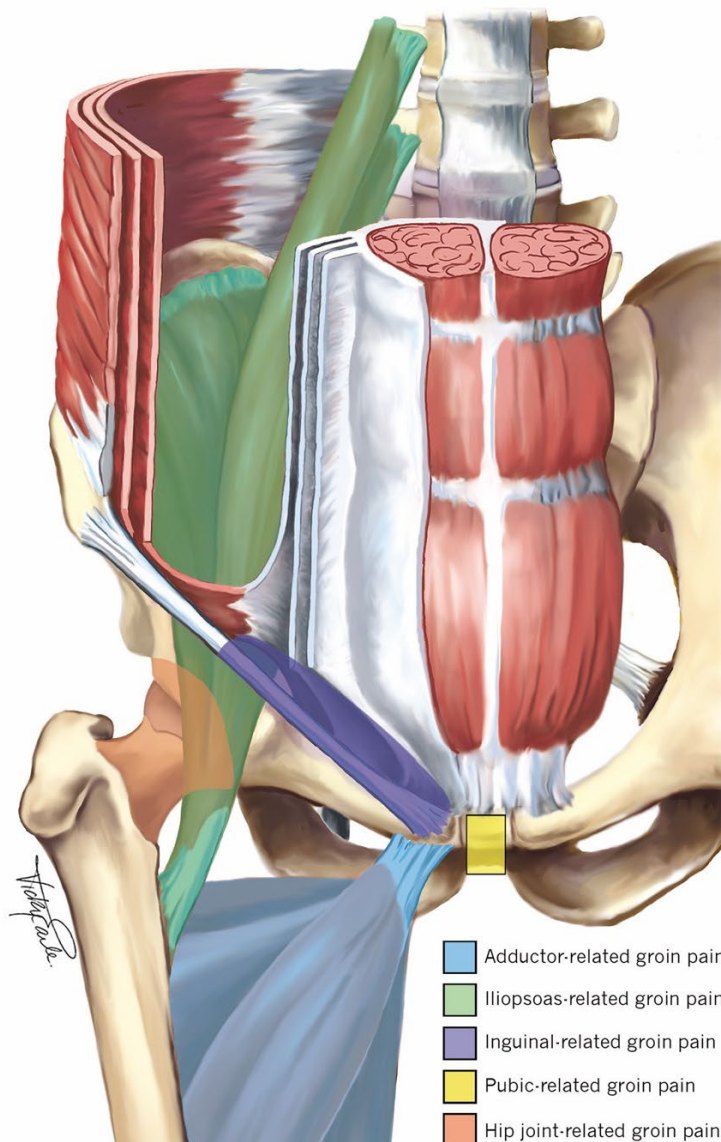
For hip joint-related groin pain the following terminology should be used to describe the diagnosis:

- (1) Femoroacetabular impingement syndrome (FAIS)
- (2) Acetabular dysplasia and/or hip instability
- (3) Conditions with or without a distinct osseous morphology (viz: ligamentum teres pathology, labral, chondral pathology and/or subspine impingement)

The term 'morphology' should be used when describing cam and/or pincer impingement.

This list of clinical entities is not exhaustive and patients presenting with groin pain may also have symptoms arising from other sources (e.g. other muscles, tendons, bones, and nerves in that region).

Pain from non-musculoskeletal conditions and red flags should not be missed where possible. These should be considered, especially if symptoms cannot easily be classified into one of the commonly defined clinical entities for groin pain.



Grade of recommendation: C

Agreement: median 8.50 (6-9)

Literature summary:

To answer the definitive question as to which terminology and definitions are recommended the group performed a scoping literature review and answered two background questions. These are presented below followed by the answer to the main question.

Literature search

The search yielded 2122 titles which were manually screened by a single author (NB). The abstracts of 90 papers were reviewed after which 37 papers were examined as full text. In the

end 7 consensus statements were identified. The details of the search are contained in appendix A at the end of this section.

Summary of classification systems published on hip joint and groin pain in young and middle-aged active individuals.

From 2014 onwards 7 consensus statements were published on the classification of hip and groin pain in athletes. These have varied in terms of their scope, the make-up of the participants and the impact they have had. This section gives an overview of the current classification systems available in the literature and is split into those with a predominant groin or hip focus.

Groin:

The first agreement in the field was the “Treatment of the Sportsman's groin': British Hernia Society's 2014 position statement based on the Manchester Consensus Conference” by Sheen et al [1]. This statement focused on pain in the inguinal canal region in athletes. They agreed that the term “hernia” was not appropriate and instead opted to use the term “inguinal disruption”. Inguinal disruption can be diagnosed when 3 of 5 specific features – based on history and physical examination are present.

The second agreement was the 2015 “Doha agreement on terminology and definitions in longstanding groin pain in athletes” by Weir et al [2]. This paper focused on 4 different clinical entities that are commonly seen in athletes. The terminology adductor, iliopsoas, pubic and inguinal related groin pain was agreed upon. These clinical entities can be diagnosed based upon features of history and physical examination. The agreement also emphasized that other causes of groin pain, such as the hip joint and other conditions, should be considered (neurological, orthopaedic, urological, gynaecological, gastroenterological etc.), with an overview of specific possibilities to consider and not to miss, but without specific definitions of the other conditions.

The third and most recent agreement on groin pain is the 2016 “Italian consensus on groin pain syndrome in athletes” by Bisciotti et al [3]. They classified groin pain into 11 different categories (articular, visceral, bone, musculotendinous, pubic symphysis related, neurological, developmental causes, genitourinary disease related causes, neoplastic, infectious, systemic) with multiple pathologies for most categories. They report a total of 63 pathologies to be considered within the 11 different categories. They also suggest classifying into traumatic, overuse or longstanding. The criteria upon which groin pain can be classified to the various pathologies are not reported in detail.

Hip:

The first paper published on hip in active individuals was the “Warwick agreement on femoroacetabular impingement syndrome: an international consensus statement” by Griffin

et al [4]. This consensus proposed the use of the term femoroacetabular impingement syndrome (FAIS) rather than just FAI. Specific terminology regarding the morphology of the hip (cam and pincer morphology) rather than terms such as deformity, abnormality or lesion was recommended. The diagnosis of FAIS should be based upon history, physical examination findings and imaging findings. A detailed description of these findings is given in the statement.

The second paper on the hip was the 2018 Consensus recommendations on the classification, definition, and diagnostic criteria of hip-related pain in young and middle-aged active adults by Reiman et al [5]. This paper describes the common hip conditions affecting young and middle-aged active individuals as being: (1) femoroacetabular impingement (FAI) syndrome, (2) acetabular dysplasia and/or hip instability and (3) other conditions without a distinct osseous morphology (labral, chondral and/or ligamentum teres conditions). A detailed literature overview on the clinical utility of physical tests to rule in or rule out these problems was presented. The need to consider both non-musculoskeletal and serious hip pathological conditions (e.g., tumours, infections, stress fractures, slipped capital femoral epiphysis) as well as competing musculoskeletal conditions was emphasized.

The International Society of hip preservation organized an international consensus on assessment and treatment of femoroacetabular impingement syndrome in 2019 [6]. They did not explicitly discuss terminology but use the term femoroacetabular impingement syndrome. For making the diagnosis of FAIS they refer the reader to the Warwick agreement and advise using the Doha agreement for extra-articular sources of groin pain. They also point out that conditions can co-exist. The need to differentiate between hip and lumbosacral sources of pain is discussed. Intra articular pathology is further sub divided into impingement, hyper and hypo mobility, but these are not further clearly defined.

The most recent paper on the hip is the 2022 Oxford consensus on primary cam morphology and femoroacetabular impingement syndrome by Dijkstra et al. [7]. This paper had a specific focus on FAIS, the terminology and taxonomy. They reinforced the suggestion of the Warwick agreement to use the term morphology when discussing cam and pincer and avoiding terms like lesion, deformity, or abnormality. They propose a distinction into primary and secondary cam morphology.

Summary of how consensus statements to date have been adopted scientifically and clinically

To date the adoption of agreement and consensus statements has not been widely evaluated. There has been only one study evaluating this.

Clinical adoption:

The clinical adoption has been studied in a single paper by Heijboer et al [8]. They performed a Delphi survey of the members of the Doha agreement meeting expert group and a separate international e-survey among clinicians who regularly assess and treat athletes with groin pain. The members of the expert group had a high response rate (23/24, 96%). Most experts (73–82%) reported having adopted the Doha agreement meeting classification system “always” or “often” in all 4 domains of practice 1) communication with patients (73%), 2) communication with colleagues (82%), 3) in research (77%), and 4) in teaching (82%).

As for the e-survey, it was completed by 51 clinicians (75%) from the IOC Research Centers and FIFA Medical Centers of Excellence. They worked in 22 different countries in 5 different continents and had multidisciplinary backgrounds. In total, 69% of international clinicians reported using the Doha agreement meeting classification; either in isolation (57%) or in combination with other classification systems (12%). The Italian consensus was used by 10% in combination with other systems and the British hernia society by 8% in combination with other systems.

Fifteen clinicians (29%) reported not using any classification system. One in seven clinicians responding to the e-survey were not aware of any consensus statements on diagnostic terminology in groin pain in athletes. Additionally, one in eight clinicians was aware of these consensus statements but preferred a different approach.

Scientific adoption

To assess the scientific adoption, we evaluated the number of times that each of the consensus statements has been cited by other papers. As the number of possible citations is also influenced by the period of time the paper has been published, we also present the data as citations per year (search performed 03-2023).

Name	Number of authors	Backgrounds	Patients involved	Based on systematic reviews?	Other	Publication year	Number of citations to date	Citations per year
British hernia society groin	14	Surgery, physio, radiology	No	No (scoping reviews)	Conference held	2014	87	10
Doha agreement groin	24	Sports med, ortho, surgery, physio, radiology	No	Yes	Used Delphi in run up and conference	2015	240	30
Italian consensus groin	41	Sports med, ortho, surgery, physio, radiology, sports physiology, physical trainer	No	No (scoping reviews)	Conference held	2016	40	7
Warwick agreement FAIS	23	Sports med, ortho, surgery, physio, radiology	Yes	No (Scoping reviews)	Conference held and endorsed by 25 clinical societies	2016	489	75
ISHA	19	Ortho, physio	No	No	Delphi process	2020	4	2

Zurich	43	Sports med, ortho, general medicine, physio, radiology, exercise science	No	No (Scoping reviews)	4 key areas covered, scoping reviews and agreement meeting	2020	54	22
Oxford consensus	18	Ortho, sports med, physical medicine, rehabilitation medicine, rheumatology, family medicine, radiology, physiotherapy, statisticians, methodologist, sports science, librarian	Yes	No (Scoping reviews and preliminary concept analysis)	Used YAHIR group of 65 experts in Delphi process	2022	2	1 (note very recent publication)

Detailed explanation:

Groin pain:

There are three different consensus with regards to groin pain. These statements are quite different. The British Hernia Society uses the term groin disruption and covers a single specific clinical entity. This has a detailed definition. The Italian consensus is very expansive in terms of the number of possible diagnoses but lacks specific criteria or definitions which restricts its usability in practice. The Doha agreement describes four common clinical entities in terms of the clinical picture and findings on examination without giving details of the exact examination techniques. It also highlights the need for awareness of other conditions, red flag diagnoses and non-musculoskeletal causes of groin pain.

In terms of scientific uptake, the Doha consensus is clearly the most widely adopted and cited, more than triple the rate of the two other statements. There has been a single study performed on clinical adoption which found that the Doha agreement has been most widely adopted in practice internationally.

Taking the scope, level of detail of description of entities defined and the clinical and scientific adoption, the consensus group recommends using the Doha agreement terminology and definitions for groin pain.

Hip pain:

In contrast to the groin the consensus statements for hip joint related groin pain tend to build on each other and are less opposed. After the Warwick agreement which recommended the use of femoroacetabular impingement syndrome as the chosen term, other statements adopted this.

The current statements can be condensed into the following terms to describe the diagnosis:

- (1) Femoroacetabular impingement syndrome (FAIS)
 - (2) Acetabular dysplasia and/or hip instability
 - (3) Conditions with or without a distinct osseous morphology (viz: ligamentum teres pathology, labral, chondral pathology and/or subspine impingement)
- The term 'morphology' should be used when describing cam and/or pincer impingement.

Further in terms of specific terminology regarding imaging there is agreement that the term morphology should be used when discussing cam and pincer, avoiding terms like: lesion, deformity, or abnormality.

The combination of existing terminology and definitions will strengthen the use of those that have been well adopted. This should reduce heterogeneity in the field which has been a serious issue in the past.

Practical advice regarding classification and definitions: The next section offers a more in-depth discussion of the actual definitions and classifications recommended on this paper.

Description of defined clinical entities for groin pain [2]

Adductor-related groin pain:

Adductor tenderness and pain on resisted adduction testing

Iliopsoas-related groin pain:

Iliopsoas tenderness.

Iliopsoas-related groin pain is more likely if there is pain on resisted hip flexion and / or pain on stretching the hip flexors

Inguinal-related groin pain:

Pain in inguinal canal region and tenderness of the inguinal canal.

No palpable inguinal hernia is present.

More likely if aggravated with abdominal resistance or Valsalva/cough/sneeze.

Pubic-related groin pain:

Local tenderness of the pubic symphysis and the immediately adjacent bone.

There are no particular resistance tests to test specifically for pubic-related groin pain.

Palpation must be precise as numerous structures in the groin are in close proximity and can refer pain to overlapping areas. The term tenderness is defined in this system as discomfort or pain when the area is palpated, and the athlete recognises this to be their specific injury pain.

The pain reported by the athlete on resistance testing should also be felt in the affected structure. For example, in adductor-related groin pain, the pain on resisted adduction testing

should reproduce the athletes' recognisable pain in the adductors. Pain felt in a different location—for example, the inguinal region on resisted adduction testing—would not signify adductor-related groin pain.

Hip-related groin pain

Femoroacetabular impingement syndrome (FAIS) [4]

FAIS is a motion-related clinical disorder of the hip comprised by a triad of symptoms, clinical signs, and imaging findings. It represents symptomatic premature contact between the proximal femur and the acetabulum

Acetabular dysplasia and/or hip instability [9]

The current Ottawa classification recommends considering acetabular dysplasia as a spectrum [9]. There are three main sub-types which are:

Anterior instability: with reduced anterior coverage or excessive version.

Posterior instability: posterior bony insufficiency with anterior wall overcoverage.

Lateral/global instability: deficiency of the superolateral acetabulum.

Table 2
Ottawa Classification for Symptomatic Acetabular Dysplasia.

Class	Clinical Findings	Radiographic Findings
Anterior (A)	Anterior hip pain Exacerbated by: - extension + external rotation - late stance phase - positive PART	- Normal LCEA (>25 degrees) - Percent anterior coverage <15% - Anterior wall index <0.30 - Excessive posterior wall coverage
Posterior (P)	Anterior + posterior hip pain ± prior diagnosis of SI joint pathology or Piriformis syndrome ± neurologic symptoms in sciatic nerve distribution Exacerbated by: - flexion + internal rotation ± axial load - ascending stairs/slope	- Normal LCEA (>25 degrees) - Percent posterior coverage <36% - Posterior wall index <0.80 - Posterior wall sign - Ischial spine sign - Crossover sign >1 cm from the acetabular roof
Lateral (L) • Anterolateral • Posterolateral • Global	Diffuse activity-related pain Abductor fatigue Symptoms of static overload	- LCEA (<20 degrees), or - LCEA 20-25 degrees and AI >10 - ± features of anterior or posterior uncoverage depending on acetabular version

AI, acetabular index; LCEA, lateral center-edge angle; PAO, periacetabular osteotomy; PART, prone apprehension/relocation

Other conditions with or without a distinct osseous morphology ([5])

These can include labral, chondral, subspine impingement and/or ligamentum teres conditions. These diagnoses can be suspected based on history and examination findings but require additional investigations to confirm or rule out.

Other conditions causing groin pain

A high index of clinical suspicion is needed to identify these. Clinicians need to be alert to the possibilities, especially if symptoms cannot easily be classified into one of the commonly defined clinical entities for the hip or groin mentioned above.

There are numerous possible causes, and a number are listed in the table below. The main categories are orthopaedic, neurological, rheumatological, urological, gastrointestinal, dermatological, oncological and surgical, but this list is not exhaustive as many rare conditions could possibly cause pain in the groin region.

Defined entities	Other musculoskeletal causes	Not to be missed
<p>Groin pain: Adductor-related groin pain Iliopsoas-related groin pain Inguinal-related groin pain Pubic-related groin pain</p> <p>Hip-related groin pain: Femoroacetabular impingement (FAI) syndrome Acetabular dysplasia and/or hip instability Other conditions without a distinct osseous morphology (labral, chondral and/or ligamentum teres conditions)</p>	<p>Inguinal or femoral hernia Post-hernioplasty pain Nerve entrapment - Ilioinguinal - Genitofemoral - Iliohypogastric Referred pain - Lumbar spine - Sacroiliac joint Apophysitis or avulsion fracture - Anterior superior iliac spine - Anterior inferior iliac spine - Pubic bone</p>	<p>Stress fracture - Neck of femur - Pubic ramus</p> <p>Hip joint - Osteoarthritis - Avascular necrosis /transient osteoporosis of the head of the femur - Arthritis of the hip joint (reactive or infectious)</p> <p>Inguinal lymphadenopathy Intra-abdominal abnormality - Prostatitis - Urinary tract infections - Kidney stone - Appendicitis - Diverticulitis</p> <p>Gynaecological conditions Spondyloarthropathies - Ankylosing spondylitis</p> <p>Tumours - Testicular tumours - Bone tumours - Prostate cancer - Urinary tract cancer - Digestive tract cancer - Soft tissue tumours</p>

References:

- 1 Sheen AJ, Stephenson BM, Lloyd DM, *et al.* "Treatment of the sportsman's groin": British Hernia Society's 2014 position statement based on the Manchester Consensus Conference. *Br J Sports Med* 2014;**48**:1079–87. doi:10.1136/bjsports-2013-092872
- 2 Weir A, Brukner P, Delahunt E, *et al.* Doha agreement meeting on terminology and definitions in groin pain in athletes. *Br J Sports Med* 2015;**49**:768–74. doi:10.1136/bjsports-2015-094869
- 3 Bisciotti GN, Volpi P, Zini R, *et al.* Groin Pain Syndrome Italian Consensus Conference on terminology, clinical evaluation and imaging assessment in groin pain in athlete. *BMJ Open Sport Exerc Med* 2016;**2**:e000142. doi:10.1136/bmjsem-2016-000142
- 4 Griffin DR, Dickenson EJ, O'Donnell J, *et al.* The Warwick Agreement on femoroacetabular impingement syndrome (FAI syndrome): an international consensus statement. *Br J Sports Med* 2016;**50**:1169–76. doi:10.1136/bjsports-2016-096743
- 5 Reiman MP, Agricola R, Kemp JL, *et al.* Consensus recommendations on the classification, definition and diagnostic criteria of hip-related pain in young and middle-aged active adults from the International Hip-related Pain Research Network, Zurich 2018. *Br J Sports Med* 2020;**54**:631–41. doi:10.1136/bjsports-2019-101453

- 6 Takla A, O'Donnell J, Voight M, *et al.* The 2019 International Society of Hip Preservation (ISHA) physiotherapy agreement on assessment and treatment of femoroacetabular impingement syndrome (FAIS): an international consensus statement. *J Hip Preserv Surg* 2021;**7**:631–42. doi:10.1093/jhps/hnaa043
- 7 Dijkstra HP, Mc Auliffe S, Ardern CL, *et al.* Oxford consensus on primary cam morphology and femoroacetabular impingement syndrome: part 1—definitions, terminology, taxonomy and imaging outcomes. *Br J Sports Med* 2022;:bjsports-2022-106085. doi:10.1136/bjsports-2022-106085
- 8 Heijboer WMP, Weir A, Delahunt E, *et al.* A Delphi survey and international e-survey evaluating the Doha agreement meeting classification system in groin pain: Where are we 5 years later? *J Sci Med Sport* 2021;:S1440244021001766. doi:10.1016/j.jsams.2021.06.014
- 9 Wilkin GP, Ibrahim MM, Smit KM, *et al.* A Contemporary Definition of Hip Dysplasia and Structural Instability: Toward a Comprehensive Classification for Acetabular Dysplasia. *J Arthroplasty* 2017;**32**:S20–7. doi:10.1016/j.arth.2017.02.067

Appendix A:

Search strategy:

Groin Injury in Athletes – A Search Strategy

Results based on Embase search.

1. exp inguinal region/
2. exp inguinal pain/
3. exp hip injury/
4. hip injury.mp
5. groin injury.mp
6. groin pain.mp
7. adductor.mp
8. iliopsoas muscle/
9. femoroacetabular impingement.mp. or exp femoroacetabular impingement/
10. 1 or 2 or 3 or 4 or 5 or 6 or 7 or 8 (94189 results)
11. Diagnosis.mp
12. Definition.mp
13. Consensus statement.mp or consensus/
14. Classification.mp
15. 10 or 11 or 12 or 13 (7215511 results)
16. Exp athlete/ or athlete.mp
17. Sports.mp or sport/
18. Young adult.mp or exp young adult/
19. 15 or 16 or 17 (530659 results)
20. 9 and 14 and 18 (2194 results)

▼ Search History (20)		
# ▲	Searches	Results
1	exp inguinal region/	18326 At
2	exp inguinal pain/	3040 At
3	exp hip injury/	57653 At
4	hip injury.mp.	2378 At
5	groin injury.mp.	213 At
6	groin pain.mp.	3129 At
7	adductor.mp.	9530 At
8	iliopsoas muscle/	2272 At
9	femoroacetabular impingement.mp. or exp femoroacetabular impingement/	5478 At
10	1 or 2 or 3 or 4 or 5 or 6 or 7 or 8 or 9	94236 At
11	Diagnosis.mp.	6215756 At
12	Definition.mp.	219525 At
13	Consensus statement.mp. or consensus/	105261 At
14	Classification.mp.	948839 At
15	11 or 12 or 13 or 14	7067549 At
16	exp athlete/ or athlete.mp.	83040 At
17	Sports.mp. or sport/	132684 At
18	Young adult.mp. or exp young adult/	530927 At
19	16 or 17 or 18	698833 At
20	10 and 15 and 19	2195 At

Medline Search Strategy

1. Inguinal.mp
2. exp Hip injuries/
3. hip injuries.mp
4. groin injuries.mp
5. groin pain.mp
6. adductor.mp
7. exp psoas muscles/ or iliopsoas.mp
8. femoroacetabular impingement.mp. or exp femoroacetabular impingement/
9. Diagnosis.mp
10. Definition.mp
11. Consensus statement.mp or consensus/
12. Classification.mp
13. Exp athletes/ or athlete.mp
14. sport.mp. or exp Sports/
15. Young adult.mp or exp young adult/
16. 1 or 2 or 3 or 4 or 5 or 6 or 7 or 8
17. 9 or 10 or 11 or 12
18. 13 or 14 or 15
19. 16 and 17 and 18

<input type="checkbox"/> # ▲ Searches	Results
<input type="checkbox"/> 1 inguinal.mp.	37356
<input type="checkbox"/> 2 exp Hip Injuries/	36047
<input type="checkbox"/> 3 hip injuries.mp.	2282
<input type="checkbox"/> 4 groin injuries.mp.	181
<input type="checkbox"/> 5 groin pain.mp.	2098
<input type="checkbox"/> 6 adductor.mp.	7218
<input type="checkbox"/> 7 exp Psoas Muscles/ or iliopsoas.mp.	3902
<input type="checkbox"/> 8 femoroacetabular impingement.mp. or exp femoroacetabular impingement/	3467
<input type="checkbox"/> 9 Diagnosis.mp.	4116588
<input type="checkbox"/> 10 Definition.mp.	148557
<input type="checkbox"/> 11 Consensus statement.mp. or consensus/	25111
<input type="checkbox"/> 12 Classification.mp.	974148
<input type="checkbox"/> 13 exp athlete/ or athlete.mp.	32501
<input type="checkbox"/> 14 sport.mp. or exp Sports/	236792
<input type="checkbox"/> 15 Young adult.mp. or exp young adult/	1031476
<input type="checkbox"/> 16 1 or 2 or 3 or 4 or 5 or 6 or 7 or 8	87962
<input type="checkbox"/> 17 9 or 10 or 11 or 12	4993345
<input type="checkbox"/> 18 13 or 14 or 15	1244080
<input type="checkbox"/> 19 16 and 17 and 18	2012

II Clinical examination

QUESTION 1

What clinical examination is relevant for determining the source of hip and groin pain?

Statement:

Always consider the mechanism of the injury, the history, and the pain pattern along with the clinical findings. It is important to note that the described clinical entities are not mutually exclusive, and they often co-exist.

Palpation of the adductors, iliopsoas, inguinal canal, and pubic symphysis should form a part of the routine clinical examination. In addition, resistance testing in hip adduction (adductors), hip flexion (rectus femoris and iliopsoas) and trunk flexion (abdominals) should be performed.

The FADIR (flexion, adduction and internal rotation) test and assessment of range of movement of the hip, specifically the flexion and the internal and external rotation, are useful for ruling out the hip joint as a source of groin pain if they do not provoke pain. Since they are not specific, it means that if they are painful the hip joint could potentially be the source of groin pain.

One should be aware that pain in the groin can radiate from different sources which can include the lumbosacral spine, SI joint, intra-abdominal or gynecological pathology.

Grade of Recommendation: C

Agreement: median 8 (4-9)

Literature Summary:

Level of Evidence	Studies
I	Nil
II	[3, 8, 13, 15, 18]
III	[2, 11, 12, 17]
IV	[6, 10, 7, 14, 16]
V	[1, 4, 5, 19]

Assessment of the hip and groin pain can be challenging as different clinical entities can

present with similar clinical symptoms. Numerous diagnostic tests for the hip and groin are used routinely for clinical evaluation. However, there is little research suggesting which tests are of the greatest value to the examiner.

A systematic approach to hip examination including newly understood hip pathologies, like FAIS, was published by Martin et al. in 2010 (1). They looked at several high-volume hip specialists in order to identify common physical examination patterns, including a basic exam and pathology-specific special testing. They recommended a 21-step evaluation of the hip, assessing four different layers: osteochondral, capsulolabral, musculotendinous, and neurovascular [1,2]. A more recent overview, which was co-authored by some members of this project, also suggests an approach for clinical examination for the hip and groin based on recent evidence [23].

Various elements of clinical examination are discussed below:

Red flags or serious pathology:

There are several serious conditions of the hip that can present with groin pain. These include avascular necrosis of the femoral head or stress fracture of the femoral neck. A previous study in patients with HIV suggested that a normal hip ROM was useful in ruling out femoral avascular necrosis. [24] For femoral neck stress fractures there is evidence that the fulcrum test can help rule this out (negative likelihood ratio 0.92, sensitivity 88%) [29].

Although the hop and lateral hop tests are often used as a sensitive but not specific test for hip stress fractures, their clinical utility has been questioned because of the lack of diagnostic studies evaluating them.

Pain from lumbar spine:

Screening tests to exclude radicular pain/discogenic pain include the slump test (negative likelihood ratio 0.32, sensitivity 83%), straight leg raise test (if negative-negative likelihood ratio 0.05, sensitivity 97%) and repeated lumbar spine ROM testing that's negative for peripheralization (negative likelihood ratio 0.12; sensitivity 92%) [25,26].

Pain from the sacroiliac joint:

The thigh thrust test had the best utility in excluding the sacroiliac joint as a source of referred pain (negative likelihood 0.18, sensitivity 88%) [27].

Hip joint:

Most of the research done on the value of clinical examination of the hip is biased by the inclusion of a very high proportion of patients with hip joint pathology in high volume settings. This limits the clinical applicability of the results as many of the tests change the post-test likelihood very little. [2]

Range of motion:

Measuring hip internal rotation (IR) in flexion appears more effective at differentiating

athletes with pain compared to hip IR in a neutral position [3]. A systematic review found that a total rotation (IR & ER) of both hips less than 85° during pre-season screening increased the risk of developing groin pain. However, no connection between internal rotation, abduction, extension, and the risk of past or present groin pain was found [11]. A cross-sectional study compared symptomatic and asymptomatic patients regarding ROM and muscle strength [12]. It found that symptomatic patients have less hip flexion, ER and IR passive ROM than healthy controls [12].

Bent knee fall out (BKFO) is a combined movement of hip flexion, abduction, and external rotation. The literature reported that a higher score on bent knee fall out, representing reduced range of motion for this test, differentiates athletes with hip/groin pain from those without pain (SMD=0.75, 95%CI: 0.24–1.27) [3]

FADIR-anterior impingement test:

When testing FADIR specifically in 90° of hip flexion, this manoeuvre is also referred to as the anterior impingement test [5]. This pain provocation test is used to assess the presence of FAIS and potentially labral pathology [7].

A meta-analysis by Reiman et al. showed that FADIR test possessed excellent sensitivity but poor specificity for the labral tear [6]. Sensitivity of FADIR to detect FAI ranges from 59 to 100% and inter-observer agreement is excellent at 96% [5], but the specificity is quite low at 24 to 26 % [8]. This test is useful for ruling out the hip as a possible source of pain. The low specificity means that a positive test can only indicate the need for further investigation of the hip [3, 4, 6, 9, 10].

Groin region:

The Doha agreement classifies groin pain from non-hip joint sources into four common clinical entities. These are defined by the presence of recognisable injury pain during palpation for iliopsoas, inguinal and pubic related groin pain. Adductor-related groin pain is present if there is both pain on palpation and resistance testing [10]. The clinical examination tests for this approach have been found to be reliable [20]. In a recent study the clinical diagnosis made between two examiners was found to be very good if athletes had a single clinical entity but lower if they presented with multiple entities [21].

In general, a lack of a defined gold standard makes simple research into the diagnostic accuracy impossible. Many studies compare the value of clinical examination to findings on imaging, where imaging is considered the reference standard. This approach is not ideal as it is well known that many healthy active individuals also have imaging abnormalities. Some studies also use the result of soft tissue surgery of the groin as a reference standard – but again this has shortcomings. This means that commonly used approaches such as specificity and sensitivities or positive and negative predictive values are not easily applicable. As such the focus should be on whether certain examination techniques can be performed in a reproducible manner. Some newer studies are also starting to examine the prevalence of which tests are painful in certain patient groups, and whether different examiners can agree

on clinical classification.

Inguinal related groin pain:

A recent study on 44 male athletes examined the interexaminer reliability of clinical examination tests with palpation and resistance testing [19]. The reliability varied from slight to substantial. The assessment of the inguinal canal with invagination for posterior wall firmness was not reliable. Recognisable pain in the inguinal canal on scrotal invagination was found in 94% of athletes with inguinal related groin pain. Four out of five of these also had pain on transabdominal palpation. The resistance test that was most often painful was the cross test.

Adductor-related groin pain:

Palpation

Palpation of the adductors is one of the criteria when diagnosing adductor-related groin pain. Tenderness (recognisable pain on palpation) can be felt on palpating the adductors. A good intraobserver and interobserver agreement for this approach ($\kappa \geq 0.70$) has been documented. [10, 20, 23].

Pain provocation on resistance testing: Adductor Squeeze Test

The adductor squeeze test is a commonly used pain provocation test. A meta-analysis for the adductor squeeze test, demonstrated strong evidence with a large effect size, that those with hip/groin pain have reduced adductor strength on this test [3]. It should be noted that only pain felt in the adductor muscle/attachment is used to make the clinical diagnosis – so if pain is felt in the lower abdomen this would not be considered diagnostic for adductor-related groin pain.

The most commonly used squeeze tests are performed at 90°, 45° and 0° of hip flexion. It has been reported that hip adduction is best assessed with the hips in 0° of hip flexion.

The greatest adductor force production is with the hips is in 0° position, while 45° flexion gives the highest EMG output [31,32].

Muscle strength Assessment:

There is evidence that the presence of hip/groin pain is associated with less adductor strength. The effect size was large (SMD=1.41, 95%CI: 0.44–2.37) [3].

Reduced hip adduction strength, and reduced hip adduction to hip abduction strength ratio are the commonly identified risk factors for groin pain [14, 15, 16]. However, there are studies reporting that a low hip adduction strength may be a risk for future groin pain but does not necessarily indicate past or present groin pain [17, 18].

Iliopsoas related groin pain

Iliopsoas related groin pain is defined as recognizable pain on palpation of the iliopsoas. It is more likely if there is pain on resisted hip flexion testing and/or on stretching of the iliopsoas.

The iliopsoas can be palpated at 2 sites:

- 1) In the triangle between the inguinal ligament, the medial edge of the sartorius muscle and the femoral artery.
- 2) At the level of the anterior iliac spine (AIS) lateral to the rectus abdominis muscle in the abdomen. [20, 30] Palpation at these locations is reliable and reproducible [20].

Pain provocation on resistance testing:

The presence of pain on resisted hip flexion should be performed supine with the hip in 90 degrees of flexion as this has been shown to be reliable and reproducible.

Muscle strength Assessment:

Strength assessment of the iliopsoas can be performed with or without objective dynamometry. Using manual testing can only identify large differences in strength between sides. Using a dynamometer allows objective and reliable measurement of the strength [33,34,35].

Pubic related groin pain

Palpation of the pubic symphysis and adjacent bone for the presence of recognizable injury pain can be performed reliably [20]. While not specific for pain from the pubic bone or symphyseal joint resistance testing of the adductor muscles clearly also stresses this joint. A study looking at athletes who had chronic groin pain and pubic bone marrow oedema on MRI found the bilateral adductor test to have higher specificity than a single leg test or testing with 45 degrees hip flexion [22].

References:

1. Martin HD, Kelly BT, Leunig M, Philippon MJ, Clohisy JC, Martin RL, et al. The pattern and technique in the clinical evaluation of the adult hip: the common physical examination tests of hip specialists. *Arthroscopy*. 2010;26(2):161-72.
2. Martin HD, Palmer IJ. History and physical examination of the hip: the basics. *Curr Rev Musculoskelet Med*. 2013;6(3):219-25.
3. Mosler AB, Agricola R, Weir A, Hölmich P, Crossley KM. Which factors differentiate athletes with hip/groin pain from those without? A systematic review with meta-analysis. *Br J Sports Med*. 2015;49(12):810.
4. Reiman MP, Mather RC, 3rd, Cook CE. Physical examination tests for hip dysfunction and injury. *Br J Sports Med*. 2015;49(6):357-61.
5. Wong SE, Cogan CJ, Zhang AL. Physical Examination of the Hip: Assessment of Femoroacetabular Impingement, Labral Pathology, and Microinstability. *Curr Rev Musculoskelet Med*. 2022;15(2):38-52.
6. Reiman MP, Goode AP, Cook CE, Hölmich P, Thorborg K. Diagnostic accuracy of clinical tests for the diagnosis of hip femoroacetabular impingement/labral tear: a systematic review with meta-analysis. *Br J Sports Med*. 2015;49(12):811.
7. Klaue K, Durnin CW, Ganz R. The acetabular rim syndrome. A clinical presentation of dysplasia of the hip. *J Bone Joint Surg Br*. 1991;73(3):423-9.
8. Pålsson A, Kostogiannis I, Ageberg E. Combining results from hip impingement and range of motion tests can increase diagnostic accuracy in patients with FAI syndrome. *Knee Surg Sports Traumatol Arthrosc*. 2020;28(10):3382-92.

9. Reiman MP, Goode AP, Hegedus EJ, Cook CE, Wright AA. Diagnostic accuracy of clinical tests of the hip: a systematic review with meta-analysis. *Br J Sports Med.* 2013;47(14):893-902.
10. Weir A, Brukner P, Delahunt E, Ekstrand J, Griffin D, Khan KM, et al. Doha agreement meeting on terminology and definitions in groin pain in athletes. *Br J Sports Med.* 2015;49(12):768-74.
11. Tak I, Engelaar L, Gouttebauge V, Barendrecht M, Van den Heuvel S, Kerkhoffs G, et al. Is lower hip range of motion a risk factor for groin pain in athletes? A systematic review with clinical applications. *Br J Sports Med.* 2017;51(22):1611-21.
12. Retchford TH, Tucker KJ, Weinrauch P, Cowan SM, Grimaldi A, Kemp JL, et al. Clinical features of people with hip-related pain, but no clinical signs of femoroacetabular impingement syndrome. *Phys Ther Sport.* 2018;34:201-7.
13. Mohammad WS, Abdelraouf OR, Elhafez SM, Abdel-Aziem AA, Nassif NS. Isokinetic imbalance of hip muscles in soccer players with osteitis pubis. *J Sports Sci.* 2014;32(10):934-9.
14. Whittaker JL, Small C, Maffey L, Emery CA. Risk factors for groin injury in sport: an updated systematic review. *Br J Sports Med.* 2015;49(12):803-9.
15. Belhaj K, Meftah S, Mahir L, Lmidmani F, Elfatimi A. Isokinetic imbalance of adductor-abductor hip muscles in professional soccer players with chronic adductor-related groin pain. *Eur J Sport Sci.* 2016;16(8):1226-31.
16. Tyler TF, Nicholas SJ, Campbell RJ, McHugh MP. The association of hip strength and flexibility with the incidence of adductor muscle strains in professional ice hockey players. *Am J Sports Med.* 2001;29(2):124-8.
17. Mosler AB, Crossley KM, Thorborg K, Whiteley RJ, Weir A, Serner A, et al. Hip strength and range of motion: Normal values from a professional football league. *J Sci Med Sport.* 2017;20(4):339-43.
18. Marušič J, Šarabon N. Hip adduction and abduction strength in youth male soccer and basketball players with and without groin pain in the past year. *PLoS One.* 2022;17(10):e0275650.
20. Heijboer WMP, Vuckovic Z, Weir A, Tol JL, Hölmich P, Serner A. Clinical examination for athletes with inguinal-related groin pain: interexaminer reliability and prevalence of positive tests. *BMJ Open Sport Exerc Med.* 2023;9(1):e001498.
21. Hölmich P, Hölmich LR, Bjerg AM. and Clinical examination of athletes with groin pain: an intraobserver and interobserver reliability study. *Br J Sports Med.* 2004; 38: 446– 451.
22. Heijboer WMP, Weir A, Vuckovic Z, Fullam K, Tol JL, Delahunt E, Serner A. Inter-examiner reliability of the Doha agreement meeting classification system of groin pain in male athletes. *Scand J Med Sci Sports.* 2023 Feb;33(2):189-196. doi: 10.1111/sms.14248. Epub 2022 Oct 29. PMID: 36259124; PMCID: PMC10092143.
23. Verrall GM, Slavotinek JP, Barnes PG, Fon GT. Description of pain provocation tests used for the diagnosis of sports-related chronic groin pain: relationship of tests to defined clinical (pain and tenderness) and MRI (pubic bone marrow oedema) criteria. *Scand J Med Sci Sports.* 2005 Feb;15(1):36-42. doi: 10.1111/j.1600-0838.2004.00380.x. PMID: 15679570.
24. Thorborg K, Reiman MP, Weir A, Kemp JL, Serner A, Mosler AB, Hölmich P. Clinical Examination, Diagnostic Imaging, and Testing of Athletes With Groin Pain: An Evidence-Based Approach to Effective Management. *J Orthop Sports Phys Ther.* 2018 Apr;48(4):239-249. doi: 10.2519/jospt.2018.7850. Epub 2018 Mar 6. PMID: 29510653.
25. Joe GO, Kovacs JA, Miller KD, et al.. Diagnosis of avascular necrosis of the hip in asymptomatic HIV-infected patients: clinical correlation of physical examination with magnetic resonance imaging. *J Back Musculoskelet Rehabil.* 2002; 16: 135– 139. <https://doi.org/10.3233/BMR-2002-16403>
26. Devillé WL, van der Windt DA, Dzaferagi A, Bezemer PD, Bouter LM. and The test of Lasègue: systematic review of the accuracy in diagnosing herniated discs. *Spine (Phila Pa 1976).* 2000; 25: 1140–1147.

27. DA van der Windt DA, , Simons E, , Riphagen II, , et al.. Physical examination for lumbar radiculopathy due to disc herniation in patients with low-back pain. *Cochrane Database Syst Rev.* 2010: CD007431. <https://doi.org/10.1002/14651858.CD007431.pub2>
28. Laslett M, , Aprill CN, , McDonald B, , Young SB. and Diagnosis of sacroiliac joint pain: validity of individual provocation tests and composites of tests. *Man Ther.* 2005; 10: 207– 218.
29. Reiman MP, Goode AP, Cook CE, Hölmich P, Thorborg K. and Diagnostic accuracy of clinical tests for the diagnosis of hip femoroacetabular impingement/labral tear: a systematic review with meta-analysis. *Br J Sports Med.* 2015; 49: 811.
30. Reiman MP, Goode AP, Hegedus EJ, et al Diagnostic accuracy of clinical tests of the hip: a systematic review with meta-analysis *British Journal of Sports Medicine* 2013;47:893-902.
31. Holmich P. Long-standing groin pain in sportspeople falls into three primary patterns, a "clinical entity" approach: a prospective study of 207 patients. *Br J Sports Med.* 2007;41(4):247-252;
32. Lovell GA, Blanch PD, Barnes CJ. EMG of the hip adductor muscles in six clinical examination tests. *Physical Therapy in Sport* 2012; 13:134-140
33. Light N, Thorborg K. The precision and torque production of common hip adductor squeeze tests used in elite football. *Journal of Science and Medicine in Sport* 2016;19(11):888-892.
34. Thorborg K, Bandholm T, Holmich P. Hip- and knee-strength assessments using a hand-held dynamometer with external belt-fixation are inter-tester reliable. *Knee Surg Sports Traumatol Arthrosc.* 2013;21(3):550-555.
35. Thorborg K, Petersen J, Magnusson SP, Holmich P. Clinical assessment of hip strength using a hand-held dynamometer is reliable. *Scand J Med Sci Sports.* 2010;20(3):493-501.
36. Ishoi L, Holmich P, Thorborg K. Measures of Hip Muscle Strength and Rate of Force Development Using a Fixated Handheld Dynamometer: Intra-Tester Intra-Day Reliability of a Clinical Set-Up. *Int J Sports Phys Ther.* 2019;14(5):715-723

QUESTION 2

Where do patients with groin pain with known intra- or extra-articular pathologies report their pain locations?

Statement:

There is considerable overlap in where patients with intra- and extra-articular pathologies report their pain. Clinicians should remember that patients can, and often do, have multiple clinical entities.

Patients who feel pain in the groin can have adductor-, iliopsoas-, inguinal-, hip joint-, or pubic-related pain.

Pain from the hip joint can also be felt independently or concomitantly in the buttock and/or lateral region of the hip.

There is considerable overlap between where patients report their pain. In general, pain corresponds to the underlying anatomical location of the clinical entity in the adductor, iliopsoas, inguinal and pubic related groin pain but not necessarily for hip joint related pain. The nature of the pain does not help to differentiate between the entities.

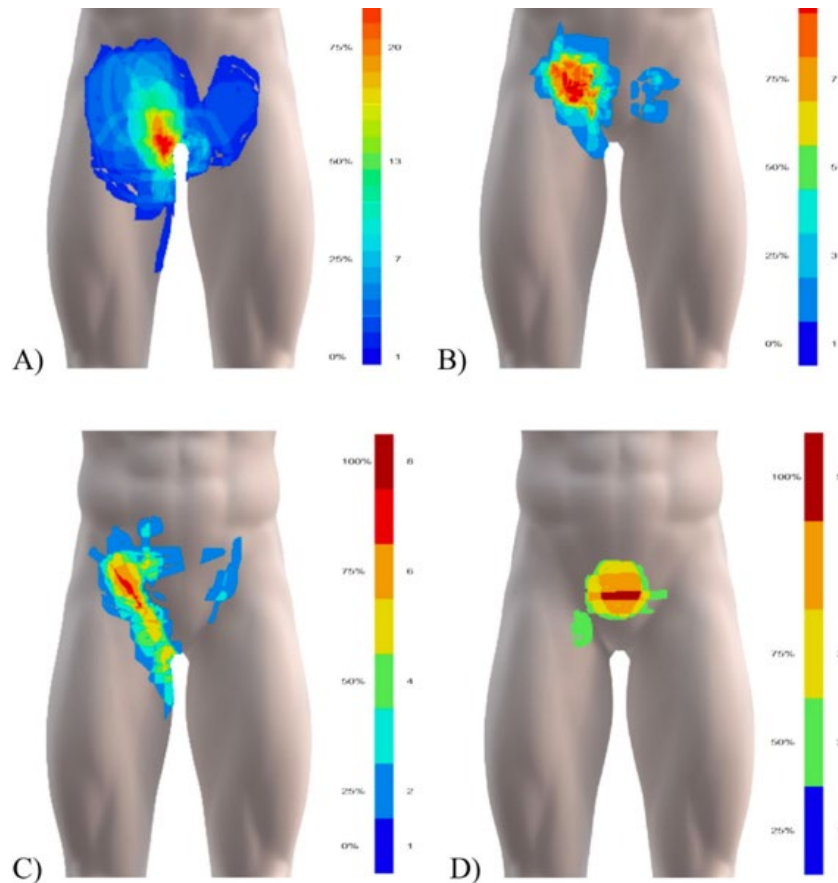


Figure 3. Pain map overlays of (A) adductor- (N=39), (B) inguinal- (N=24), (C) iliopsoas- (N=18), and (D) pubic-related (N=7) groin pain showing common regions for each clinical entity. The colour-scheme range reflects the maximum overlap and the minimum one overlapping area, shown in percent and the absolute number of drawings. Areas drawn by only one individual are not shown in the summary figures. Before overlaying, unilateral left-sided pain drawings were flipped right, and bilateral pain drawings flipped, so the largest drawn area is on the right side.

Grade of recommendation: C

Agreement : median 8.50 (6-9)

Literature Summary:

Level of Evidence

- I
- II
- III
- IV
- V

Studies

- Nil
- [2, 10, 17]
- [7, 12]
- Nil
- [1, 3-6, 8, 13, 15, 16]

The literature review identified only a limited number of studies with the majority focused on intra articular sources of hip pain.

Intra articular hip joint pain

The hip joint should always be assessed during the examination of patients reporting groin pain. A systematic review and meta-analysis focusing on the history of hip-related groin pain reported the diagnostic accuracy of subjective examination findings (patient history or self-report) associated with hip pathology [17]. No patient history items were reported to have a positive likelihood ratio higher than 2.0 this means that no patient history items alter post-test probability enough to confirm FAIS or labral pathology [11, 14].

FAIS: Pain may also be felt in the back, buttock, or thigh. Patients may also describe clicking, catching, locking, stiffness, restricted range of motion, or giving way [8]. In a paper by Philippon et al. on over 300 patients undergoing hip arthroscopies for FAIS, 85% of patients reported moderate or marked pain with the most common pain location being in the groin (81%). Range of motion was reduced in the injured hip of patients who had degenerative changes [18].

Synovitis: There were no specific studies identified. Expert opinion states that patients often report considerable groin pain with nocturnal pain and pain at rest [3]

Hip osteoarthritis (OA): There are a few studies examining where patients with hip OA report their pain. Pain varies depending on the severity and is often localized to the groin, buttock, and the greater trochanteric region. A study by Poulsen et al. found that the most identified location on pain drawings was the trochanteric region (77%), followed by the groin (53%) and the buttock area (38%) [12]. Pain radiating distal to the knee is less likely to be related to hip osteoarthritis, although it can still be present in up to half of all cases [10].

General hip pain: It is generally accepted that hip pain originating from an intra-articular source is usually felt in the groin [6, 16].

A study on the accuracy of digital hip pain drawings to diagnose nonarthritic intra-articular hip pain used a response to an intra-articular injection in 83 patients to examine where their pain was located. It found a sensitivity of 0.69 and specificity of 0.68 for intra-articular source of pain in nonarthritic hips for anterior hip pain. Lateral and posterior hip pain were not reliable to rule out intra-articular hip disease. [7].

Arnold et al., using a new pain “circle” diagram, demonstrating that in patients who had relief from intra-articular injection those who indicated the central groin and lateral trochanteric pain were much more likely to improve with intra-articular injection. This is an important point as trochanteric pain is often thought to be extra-articular in nature [2].

Adductor- iliopsoas- inguinal and pubic related groin pain:

The typical location of pain in patients with the entities later included in the Doha agreement was first described based on 207 patients examined systematically defining the entity approach. The adductor-related pain is mainly located deep medially in the groin, the

iliopsoas-related pain is located anteriorly on the proximal thigh and the inguinal(abdominal)-related pain is located around and just above the inguinal ligament centrally in the groin [21].

A pain mapping study of 167 patients seen by a single expert abdominal surgeon was performed [19]. The surgeon used history and physical examination to classify groin pain according to the Doha agreement Patients could be diagnosed with multiple entities, but those with intra-articular hip pain were excluded from the study. The patients indicated their pain on a digital pain map prior to being examined. They found that the groin pain was most often reported to be electric (22%), pain (19%) or dull/aching (15%). The type of pain did not differ between the clinical entities. There is considerable overlap between where patients report their pain but in general this roughly corresponds to the underlying anatomical location of the entity in adductor, inguinal and pubic related groin pain. With an increasing number of clinical entities, the area reported to be painful also increases [20].

References:

1. Altman R, Alarcón G, Appelrouth D, Bloch D, Borenstein D, Brandt K, Brown C, Cooke T, Daniel W, Feldman D, Greenwald R, Hochberg M, Howell D, Ike R, Kapila P, Kaplan D, Koopman W, Marino C, McDonald E, McShane D, Medsger T, Michel B, Murphy W, Osial T, Ramsey-Goldman R, Rotshchild B, Wolfe F (1991) The American College of Rheumatology criteria for the classification and reporting of osteoarthritis of the hip. *Arthritis & Rheumatism* 34(5):505–514
2. Arnold DR, Keene JS, Blankenbaker DG, DeSmet AA (2011) Hip pain referral patterns in patients with labral tears: Analysis based on intra-articular anesthetic injections, hip arthroscopy, and a new pain “circle” diagram. *Physician and Sportsmedicine* DOI: 10.3810/psm.2011.02.1859
3. Brukner P, Clarsen B, Cook J, Cools A, Crossley K, Hutchinson M, McCrory P, Bahr R, Khan K (2018) Brukner and Khan’s Clinical Sports Medicine—Volume 1: Injuries, 5th Edition. *Med Sci Sports Exerc*
4. Burnett RSJ, Della Rocca GJ, Prather H, Curry M, Maloney WJ, Clohisy JC (2006) Clinical presentation of patients with tears of the acetabular labrum. *Journal of Bone and Joint Surgery*
5. Chamberlain R (2021) Hip Pain in Adults: Evaluation and Differential Diagnosis. *Am Fam Physician*
6. Dick AG, Houghton JM, Bankes MJK (2018) An approach to hip pain in a young adult. *BMJ (Online)* DOI: 10.1136/bmj.k1086
7. Feng R, Hatem M, Martin HD (2023) Anterior Electronic Hip Pain Drawings Are Helpful for Diagnosis of Intra-articular Sources of Pain: Lateral or Posterior Drawings Are Unreliable. *Arthrosc Sports Med Rehabil* DOI: 10.1016/j.asmr.2022.10.011
8. Griffin DR, Dickenson EJ, O’Donnell J, Agricola R, Awan T, Beck M, Clohisy JC, Dijkstra HP, Falvey E, Gimpel M, Hinman RS, Hölmich P, Kassarian A, Martin HD, Martin R, Mather RC, Philippon MJ, Reiman MP, Takla A, Thorborg K, Walker S, Weir A, Bennell KL (2016) The Warwick Agreement on femoroacetabular impingement syndrome (FAI syndrome): An international consensus statement. *Br J Sports Med* DOI: 10.1136/bjsports-2016-096743
9. Kemp JL, Makdissi M, Schache AG, Pritchard MG, Crossley KM (2013) Hip chondropathy is prevalent at arthroscopy and is associated with co-existing pathology, but not patient reported outcomes. *Osteoarthritis Cartilage* DOI: 10.1016/j.joca.2013.02.293

10. Khan AM, McLoughlin E, Giannakas K, Hutchinson C, Andrew JG (2004) Hip osteoarthritis: Where is the pain? *Ann R Coll Surg Engl* DOI: 10.1308/003588404322827518
11. Owusu-Akyaw KA, Hutyra CA, Evanson RJ, Cook CE, Reiman M, Mather RC (2019) Concurrent validity of a patient self-administered examination and a clinical examination for femoroacetabular impingement syndrome. *BMJ Open Sport Exerc Med* DOI: 10.1136/bmjsem-2019-000574
12. Poulsen E, Overgaard S, Vestergaard JT, Christensen HW, Hartvigsen J (2016) Pain distribution in primary care patients with hip osteoarthritis. *Fam Pract* DOI: 10.1093/fampra/cmw071
13. Thorborg K, Reiman MP, Weir A, Kemp JL, Serner A, Mosler AB, Hölmich P (2018) Clinical examination, diagnostic imaging, and testing of athletes with groin pain: An evidence-based approach to effective management. *Journal of Orthopaedic and Sports Physical Therapy*
14. Tijssen M, van Cingel REH, de Visser E, Hölmich P, Nijhuis-van der Sanden MWG (2017) Hip joint pathology: relationship between patient history, physical tests, and arthroscopy findings in clinical practice. *Scand J Med Sci Sports* DOI: 10.1111/sms.12651
15. Weir A, Brukner P, Delahunt E, Ekstrand J, Griffin D, Khan KM, Lovell G, Meyers WC, Muschaweck U, Orchard J, Paajanen H, Philippon M, Reboul G, Robinson P, Schache AG, Schilders E, Serner A, Silvers H, Thorborg K, Tyler T, Verrall G, De Vos RJ, Vuckovic Z, Hölmich P (2015) Doha agreement meeting on terminology and definitions in groin pain in athletes. *Br J Sports Med*
16. Wilson JJ, Furukawa M (2014) Evaluation of the patient with hip pain. *Am Fam Physician*
17. Wright AA, Ness BM, Donaldson M (2021) Diagnostic Accuracy of Patient History in the Diagnosis of Hip-Related Pain: A Systematic Review. *Arch Phys Med Rehabil*
18. Philippon MJ, Maxwell RB, Johnston TL, Schenker M, Briggs KK. Clinical presentation of femoroacetabular impingement. *Knee Surg Sports Traumatol Arthrosc.* 2007 Aug;15(8):1041-7. doi: 10.1007/s00167-007-0348-2. Epub 2007 May 12. PMID: 17497126.
19. Serner A, Reboul G, Lichau O, Weir A, Heijboer W, Vuckovic Z, Boudreau SA. Digital body mapping of pain quality and distribution in athletes with longstanding groin pain. *Sci Rep.* 2022 Jun 13;12(1):9789. doi: 10.1038/s41598-022-13847-1. PMID: 35697738; PMCID: PMC9192634.
20. Nielsen MF, Ishøi L, Juhl C, Hölmich P, Thorborg K. Pain provocation tests and clinical entities in male football players with longstanding groin pain are associated with pain intensity and disability. *Musculoskelet Sci Pract.* 2023 Feb;63:102719. doi: 10.1016/j.msksp.2023.102719. Epub 2023 Jan 10. PMID: 36736197.
21. Hölmich P. Long-standing groin pain in sportspeople falls into three primary patterns, a "clinical entity" approach: a prospective study of 207 patients. *Br J Sports Med.* 2007 Apr;41(4):247-52; discussion 252. doi: 10.1136/bjsem.2006.033373. Epub 2007 Jan 29. PMID: 17261557; PMCID: PMC2658954.

QUESTION 3

Is there an association of clinical examination tests of the hip and groin region and imaging findings?

Statement:

There is a high prevalence of positive imaging findings in asymptomatic physically active individuals. A lack of imaging findings does not rule out a clinical diagnosis.

A decrease in internal rotation in 90° of hip flexion, and/ or hip abduction have been suggested to be associated with a higher alpha angle. However, it should be noted that a change of hip rotation is not only related to the alpha angle, but also to the femoral neck torsion and/or acetabular version.

In adductor-related groin pain US can be a useful modality associated with palpation pain at the insertion but until now without evidence-based support. There is no high-level evidence to support an association of clinical examination tests and imaging findings in relation to inguinal related groin pain. No studies have examined the association between clinical examination and imaging findings in iliopsoas-related groin pain.

Grade of recommendation: C

Agreement : median 8.50 (4-9)

Literature Summary:

Level of Evidence	Studies
I	Nil
II	[3–5, 10]
III	[1, 7–9, 11]
IV	[2]
V	[6, 13, 14]

The role of imaging in patients with hip and groin pain, especially in those patients that during the clinical examination, can already be classified into one or more of the previously stated categories (hip joint-, adductor-, iliopsoas-, inguinal-, and pubic-related groin pain), is unclear. There can be discrepancies between clinical and imaging findings. Excessive or inappropriate imaging can create confusion because magnetic resonance imaging (MRI) changes are common in asymptomatic active individuals and are often associated with sports or general activities. This means that morphology and imaging findings alone are not necessarily pathological [1, 6].

Clinical decision-making should carefully analyse the association of patient history and physical examination with imaging [13]. Different literature reviews reported multiple issues in assessing the association between clinical examination, symptoms, and imaging due to lack of or inadequate control group, small sample sizes, lack of or incomplete clinical information on participants, unknown reliability of the assessment of the imaging findings reported, confusing terminology and undefined diagnostic labels [2, 14].

Adductor related groin pain

Bone marrow oedema (BME) imaging findings in the pubic bones and the pubic symphysis are common in athletes, both in symptomatic as well as asymptomatic athletes [1,2]. A study comparing football players with and without groin pain found higher grades of pubic bone marrow oedema and a protrusion of the symphyseal joint disc to be associated with groin pain. Age, type of sport, loading, and the symptoms need to be taken into consideration when interpreting imaging findings. In adductor-related groin pain US can be a useful modality but until now without evidence-based support [16, 17].

In adolescents, it has been shown that pubic-related groin pain can be due to apophysitis [18]. The apophyses can be imaged with computed tomography, but this requires a relatively high dose of ionizing radiation. MRI with special ZTE sequences is a better alternative than CT as it avoids radiation and also shows oedema and the soft tissues [19].

Pubic related groin pain

Eighty-nine Australian rules football players with and without groin symptoms underwent clinical examination followed by history. Three pain provocation tests were performed (named as the Single Adductor, Squeeze and Bilateral Adductor tests). All athletes subsequently underwent MRI of their groin region for the presence of significant pubic bone marrow oedema (BMO). Of the 89, 47 were defined as having chronic groin pain, and 46 had significant BMO with 37 having both chronic groin pain and BMO. The authors concluded that if positive, all three pain provocation tests demonstrated a high likelihood for the athlete having MRI-detected parasymphyseal pubic BMO. It was also clear that some athletes without groin pain also had pubic bone marrow oedema [15].

In a large 383 cohort of patients with athletic groin pain examined associations between clinical and MRI findings [5]. The presence of pubic bone marrow oedema was correlated with the side of the pain felt (positive predictive value for bone marrow oedema on the side of the pain (left 86%, right 92%). The presence of bone marrow oedema was not associated with having a lower hip joint range of motion. A lack of tenderness on palpation of the pubic symphysis was the best test to rule out changes of the pubic aponeurosis on MRI (negative likelihood ratio 0.22). A lack of pain on palpation of the adductors was also useful to rule out MRI changes of the adductor insertion (negative likelihood ratio 0.11).

Inguinal related groin pain

There is no high-level evidence to support an association of clinical examination tests and imaging findings in relation to inguinal related groin pain.

Attention has been given to the presence of bulging or weakness of the posterior wall of the inguinal canal during Valsalva as playing a role in inguinal related groin pain. The exact role of bulging is still unclear [17]. Clinical examination of the presence of bulging during scrotal invagination has a fair reliability (Kappa 0.29 (0.05-0.52) between experienced observers [20]. The same study also found that assessing the posterior wall to be firm or soft had a reliability equivalent only to chance (Kappa 0.01 (-0.38-0.40). To date no studies have been published

looking at the inter observer reliability of the presence of dynamic changes such as bulging on US.

Studies on athletes undergoing surgery for inguinal related groin pain show that an MRI can be normal [21,22]. There are indications that a dynamic US might be useful [21]. If there is doubt about whether an actual inguinal hernia is present then dynamic US can give additional information, especially in cases where obesity impairs clinical examination.

Iliopsoas related groin pain

No studies have examined the association between clinical examination and imaging findings in iliopsoas-related groin pain.

In a large cohort (n=638) of athletes with groin pain with both acute and gradual onset 134 were identified on MRI with iliopsoas related pathology [23]. The MRI changes could be separated in 2 groups, one that showed signs of peritendinitis (66/638) and one that showed signs of muscle strain (68/638). The group that showed signs of peritendinitis had significantly longer return to sport time.

Anterior snapping hip is common in asymptomatic individuals. A detailed study using dynamic US showed that the most common causes was a flipping of the iliopsoas tendon around the iliac muscle [25], but it can also be the result of the iliopsoas tendon moving suddenly across different bony prominences in the pelvis [24].

Hip-related groin pain

In order to assess the association between range of motion and alpha angle in patients with longstanding hip and groin pain Estberger looked at 72 patients. Passive hip range of motion was measured in flexion, internal rotation with 90° hip flexion, internal rotation in neutral hip position, external rotation with 90° hip flexion, and abduction. The alpha angle was calculated from a frog-leg lateral radiograph. Lower range of motion in internal rotation in flexion, external rotation with 90° hip flexion, and abduction were associated with higher alpha angle. Internal rotation of 27° or less displayed good sensitivity (81%) and specificity (85%) to detect an alpha angle above 60°, while a cut-off of 41° in external rotation and 27° in abduction showed a sensitivity of 72% and specificity of 50% and 60%, respectively. [4]

Similarly, 334 patients were retrospectively studied for the femoral alpha angle on magnetic resonance images (MRI). Hip pain and internal rotation angles as well as results of impingement tests were reviewed. Cases with alpha angles $\geq 55^\circ$ were younger ($p = 0.005$), suffered more frequently from pain ($p < 0.001$), and were more likely to have positive impingement testing and reduced internal rotation (< 20 degrees). [8].

Consecutive testing with the FADIR, foot progression angle walking testing, and maximal squat tests may be used as a clinical combination to screen for FAI morphology on imaging, but clinical examination should not be used to confirm FAIS diagnosis without imaging [3].

References:

1. Branci S, Thorborg K, Bech BH, Boesen M, Nielsen MB, Hölmich P (2015) MRI findings in soccer players with long-standing adductor-related groin pain and asymptomatic controls. *Br J Sports Med* DOI: 10.1136/bjsports-2014-093710
2. Branci S, Thorborg K, Nielsen MB, Hölmich P (2013) Radiological findings in symphyseal and adductor-related groin pain in athletes: A critical review of the literature. *Br J Sports Med*
3. Caliesch R, Sattelmayer M, Reichenbach S, Zwahlen M, Hilfiker R (2020) Diagnostic accuracy of clinical tests for cam or pincer morphology in individuals with suspected FAI syndrome: A systematic review. *BMJ Open Sport Exerc Med*
4. Estberger A, Pålsson A, Kostogiannis I, Ageberg E (2021) Less hip range of motion is associated with a greater alpha angle in people with longstanding hip and groin pain. *Knee Surgery, Sports Traumatology, Arthroscopy* DOI: 10.1007/s00167-021-06733-2
5. Falvey ÉC, King E, Kinsella S, Franklyn-Miller A (2016) Athletic groin pain (part 1): a prospective anatomical diagnosis of 382 patients—clinical findings, MRI findings and patient-reported outcome measures at baseline. *Br J Sports Med* 50(7):423–430
6. Frank JM, Harris JD, Erickson BJ, Slikker W, Bush-Joseph CA, Salata MJ, Nho SJ (2015) Prevalence of femoroacetabular impingement imaging findings in asymptomatic volunteers: A systematic review. *Arthroscopy - Journal of Arthroscopic and Related Surgery*
7. Freitas A, Rosa TM, de Macedo Neto SL, de Carvalho Bandeira V, de Macedo Souto DR, Barin FR (2022) FABREX: A NEW CLINICAL TEST FOR DIAGNOSIS GLUTEAL TENDINOPATHY. *Acta Ortop Bras* DOI: 10.1590/1413-785220223002241045
8. Guler O, Isyar M, Karataş D, Ormeci T, Cerci H, Mahirogullar M (2016) A retrospective analysis on the correlation between hip pain, physical examination findings, and alpha angle on MR images. *J Orthop Surg Res* DOI: 10.1186/s13018-016-0476-9
9. Haskel JD, Kaplan DJ, Fried JW, Youm T, Samim M, Burke C (2021) The Limited Reliability of Physical Examination and Imaging for Diagnosis of Iliopsoas Tendinitis. *Arthroscopy - Journal of Arthroscopic and Related Surgery* DOI: 10.1016/j.arthro.2020.12.184
10. Ortiz-Declet V, Chen AW, Maldonado DR, Yuen LC, Mu B, Domb BG (2019) Diagnostic accuracy of a new clinical test (resisted internal rotation) for detection of gluteus medius tears. *J Hip Preserv Surg* DOI: 10.1093/jhps/hnz046
11. Robinson P, Barron DA, Parsons W, Grainger AJ, Schilders EMG, O'Connor PJ (2004) Adductor-related groin pain in athletes: Correlation of MR imaging with clinical findings. *Skeletal Radiol* DOI: 10.1007/s00256-004-0753-2
12. Serner A, Weir A, Tol JL, Thorborg K, Roemer F, Guermazi A, Hölmich P (2016) Can standardised clinical examination of athletes with acute groin injuries predict the presence and location of MRI findings? *Br J Sports Med* DOI: 10.1136/bjsports-2016-096290
13. Thorborg K, Reiman MP, Weir A, Kemp JL, Serner A, Mosler AB, Hölmich P (2018) Clinical examination, diagnostic imaging, and testing of athletes with groin pain: An evidence-based approach to effective management. *Journal of Orthopaedic and Sports Physical Therapy*
14. Weir A, Brukner P, Delahunt E, Ekstrand J, Griffin D, Khan KM, Lovell G, Meyers WC, Muschaweck U, Orchard J, Paajanen H, Philippon M, Rebol G, Robinson P, Schache AG, Schilders E, Serner A, Silvers H, Thorborg K, Tyler T, Verrall G, De Vos RJ, Vuckovic Z, Hölmich P (2015) Doha agreement meeting on terminology and definitions in groin pain in athletes. *Br J Sports Med*
15. Verrall GM, Slavotinek JP, Barnes PG, Fon GT. Description of pain provocation tests used for the diagnosis of sports-related chronic groin pain: relationship of tests to defined clinical (pain and tenderness) and MRI (pubic bone marrow oedema) criteria. *Scand J Med Sci Sports*. 2005 Feb;15(1):36-42. doi: 10.1111/j.1600-0838.2004.00380.x. PMID: 15679570.
16. Hölmich P, Bachmann Nielsen M. Ultrasound findings in adductor related groin pain. *Ultraschall Med*. 2006;27:509-511. <https://doi.org/10.1055/s-2006-958487>

17. Dallaudiere B, Sylvain B, Poussange N, Reboul G, Silvestre A, Meyer P, Hocquelet A, Pesquer L. Ultrasound feature variants of the adductor longus tendon in asymptomatic sportive subjects: Management implications. *Eur J Radiol.* 2021 Nov;144:109928. doi: 10.1016/j.ejrad.2021.109928. Epub 2021 Sep 20. PMID: 34562742.
18. Saily M, Whiteley R, Read JW, Giuffre B, Johnson A, Hölmich P. Pubic apophysitis: a previously undescribed clinical entity of groin pain in athletes. *Br J Sports Med.* 2015;49:828-834. <https://doi.org/10.1136/bjsports-2014-094436>
19. Koh E, Boyle J. Pubic apophysitis in elite Australian Rules football players: MRI findings and the utility of VIBE sequences in evaluating athletes with groin pain. *Clin Radiol.* 2020 Apr;75(4):293-301. doi: 10.1016/j.crad.2019.12.022. Epub 2020 Feb 1. PMID: 32019672.
20. Heijboer WMP, Vuckovic Z, Weir A, Tol JL, Hölmich P, Serner A. Clinical examination for athletes with inguinal-related groin pain: interexaminer reliability and prevalence of positive tests. *BMJ Open Sport Exerc Med.* 2023 Jan 11;9(1):e001498. doi: 10.1136/bmjsem-2022-001498. PMID: 36643406; PMCID: PMC9835948.
21. Bou Antoun M, Reboul G, Ronot M, Crombe A, Poussange N, Pesquer L. Imaging of inguinal-related groin pain in athletes. *Br J Radiol.* 2018 Dec;91(1092):20170856. doi: 10.1259/bjr.20170856. Epub 2018 Jul 25. PMID: 29947268; PMCID: PMC6319843
22. Paajanen H, Brinck T, Hermunen H, Airo I. Laparoscopic surgery for chronic groin pain in athletes is more effective than nonoperative treatment: a randomized clinical trial with magnetic resonance imaging of 60 patients with sportsman's hernia (athletic pubalgia). *Surgery.* 2011 Jul;150(1):99-107. doi: 10.1016/j.surg.2011.02.016. Epub 2011 May 5. PMID: 21549403.
23. Tsukada S, Niga S, Nihei T, et al. Iliopsoas Disorder in Athletes with Groin Pain: Prevalence in 638 Consecutive Patients Assessed with MRI and Clinical Results in 134 Patients with Signal Intensity Changes in the Iliopsoas. *JB JS Open Access.* 2018;3(1):e0049.
24. Musick SR, Varacallo M. Snapping Hip Syndrome. [Updated 2023 Aug 4]. In: StatPearls [Internet]. Treasure Island (FL): StatPearls Publishing; 2023 Jan-. Available from: <https://www.ncbi.nlm.nih.gov/books/NBK448200/>
25. Deslandes M, Guillin R, Cardinal E, Hobden R, Bureau NJ. The snapping iliopsoas tendon: new mechanisms using dynamic sonography. *AJR Am J Roentgenol.* 2008 Mar;190(3):576-81. doi: 10.2214/AJR.07.2375. PMID: 18287424.

QUESTION 4

Are clinical examination tests able to identify hip joint-related causes of groin pain in physically active adults?

Statement:

It is difficult to diagnose hip joint related groin pain based on a single clinical examination test.

Patients can have both intra- and extra- articular sources of groin pain.

Clinical examination needs to be interpreted in conjunction with medical history and imaging studies and/or diagnostic injections where appropriate to make a diagnosis.

If testing the ROM of the hip joint and/or the FADIR test reproduces their groin pain, the hip should be considered as a possible cause of groin pain. If testing the ROM of the hip joint and the FADIR test do not reproduce their groin pain, then the hip joint is unlikely to be the source of pain.

If both muscle resistance testing and palpation of the same muscle reproduce their groin pain, then extra articular muscle/tendons are a likely source.

Grade of recommendation: C

Agreement : median 9 (7-9)

Literature Summary:

Level of Evidence	Studies
I	Nil
II	[5, 8, 9]
III	[6, 7, 10, 12]
IV	[2, 11]
V	[1, 3, 4, 13, 14]

There are many causes of groin pain including; hip joint-related, adductor-related, iliopsoas-related, inguinal- related and pubic-related groin pain. These 5 main sources of groin pain have been described and defined in the terminology section. Identifying hip-joint related groin pain has been challenging. A previous review article classified the type of pain, in which hip joint-related causes included labral tear, loose bodies, FAIS, synovitis, tears of the ligamentum teres and chondral injury [4]. Further diseases of hip joint could be slipped capital femoral epiphysis, arthritic changes, avascular necrosis, and tumour [14].

Less common causes like intra-abdominal or intra-pelvic disease, extra-articular impingement, internal or external snapping hip, deep gluteal syndrome, lumbar spine and sacroiliac joint pain should be considered if the presentation does not fit with a more common entity [3, 4]. A careful history along with clinical examination and assessment is critical [14].

Femoroacetabular Impingement Syndrome and labral tear

Tijssen et al reported that the anterior impingement test, FABER, and straight leg raise (SLR) tests were found to be greater than 90% specific for intra-articular hip pathology among the studies analysed [12]. However, due to heterogenous data, the study concluded that not

enough uniform literature exists to reliably diagnose FAIS and/or labral pathology with the physical examination alone [12]. A meta-analysis by Reiman et al concluded that FADIR (0.94 to 0.97 sensitive) and flexion, internal rotation (0.96 sensitive) were the only examination tests that were investigated in enough studies of substantial quality to direct clinical decision making [11].

Ligamentum teres injury: The test was found to have a specificity of 0.85, sensitivity of 0.90, positive predictive value of 0.84, and negative predictive value of 0.91[10].

Diagnostic intra-articular injection

There are indications that precise anaesthetic injections, US or fluoroscopically guided, are helpful in deciding if groin pain originates from the hip joint [15]. A systematic review from 2023 [16] including 6 studies comparing surgical outcome of patients with FAIS with a significant pain relief after intra-articular anesthetic injection with those without. 5 studies found that a greater reduction in pain with the injection indicated a better surgical outcome. High risk of bias was observed for all studies, with prognostic factor measurement, presence of confounding factors and study attrition being the main sources of bias.

References:

1. Beck B, Drysdale L (2021) Risk Factors, Diagnosis and Management of Bone Stress Injuries in Adolescent Athletes: A Narrative Review. *Sports*
2. Bray EDR, Sherafati M, Cutts CL, Stafford GH (2015) The young adult hip: extra-articular causes of hip pain and how to pick the winners. *J Hip Preserv Surg* DOI: 10.1093/jhps/hnv012
3. Chamberlain R (2021) Hip Pain in Adults: Evaluation and Differential Diagnosis. *Am Fam Physician*
4. Frangiamore S, Mannava S, Geeslin AG, Chahla J, Cinque ME, Philippon MJ (2017) Comprehensive Clinical Evaluation of Femoroacetabular Impingement: Part 1, Physical Examination. *Arthrosc Tech* DOI: 10.1016/j.eats.2017.03.027
5. Ganderton C, Semciw A, Cook J, Pizzari T (2017) Demystifying the Clinical Diagnosis of Greater Trochanteric Pain Syndrome in Women. *J Womens Health* DOI: 10.1089/jwh.2016.5889
6. Haskel JD, Kaplan DJ, Fried JW, Youm T, Samim M, Burke C (2021) The Limited Reliability of Physical Examination and Imaging for Diagnosis of Iliopsoas Tendinitis. *Arthroscopy - Journal of Arthroscopic and Related Surgery* DOI: 10.1016/j.arthro.2020.12.184
7. Kaltenborn A, Bourg CM, Gutzeit A, Kalberer F (2014) The hip lag sign - Prospective blinded trial of a new clinical sign to predict hip abductor damage. *PLoS One* DOI: 10.1371/journal.pone.0091560
8. Martin HD, Kivlan BR, Palmer IJ, Martin RRL (2014) Diagnostic accuracy of clinical tests for sciatic nerve entrapment in the gluteal region. *Knee Surgery, Sports Traumatology, Arthroscopy* DOI: 10.1007/s00167-013-2758-7
9. Maslowski E, Sullivan W, Forster Harwood J, Gonzalez P, Kaufman M, Vidal A, Akuthota V (2010) The Diagnostic Validity of Hip Provocation Maneuvers to Detect Intra-Articular Hip Pathology. *PM and R* 2(3):174–181
10. O'Donnell J, Economopoulos K, Singh P, Bates D, Pritchard M (2014) The ligamentum teres test: A novel and effective test in diagnosing tears of the ligamentum teres. *American Journal of Sports Medicine* DOI: 10.1177/0363546513510683
11. Reiman MP, Goode AP, Cook CE, Hölmich P, Thorborg K (2015) Diagnostic accuracy of clinical tests for the diagnosis of hip femoroacetabular impingement/labral tear: A systematic review with meta-analysis. *Br J Sports Med*

12. Tijssen M, Van Cingel R, Willemsen L, De Visser E (2012) Diagnostics of femoroacetabular impingement and labral pathology of the hip: A systematic review of the accuracy and validity of physical tests. *Arthroscopy - Journal of Arthroscopic and Related Surgery*
13. Walker P, Ellis E, Scofield J, Kongchum T, Sherman WF, Kaye AD (2021) Snapping hip syndrome: A comprehensive update. *Orthop Rev (Pavia)*
14. Weir A, Brukner P, Delahunt E, Ekstrand J, Griffin D, Khan KM, Lovell G, Meyers WC, Muschaweck U, Orchard J, Paajanen H, Philippon M, Reboul G, Robinson P, Schache AG, Schilders E, Serner A, Silvers H, Thorborg K, Tyler T, Verrall G, De Vos RJ, Vuckovic Z, Hölmich P (2015) Doha agreement meeting on terminology and definitions in groin pain in athletes. *Br J Sports Med*
15. Pålsson A, Kostogiannis I, Ageberg E. Combining results from hip impingement and range of motion tests can increase diagnostic accuracy in patients with FAI syndrome. *Knee Surg Sports Traumatol Arthrosc.* 2020 Oct;28(10):3382-3392. doi: 10.1007/s00167-020-06005-5. Epub 2020 Apr 25. PMID: 32335699; PMCID: PMC7511272.
16. Martins EC, Gomes DA, de Brito Fontana H, Fernandes DA. Does response to preoperative intra-articular anesthetic injections predict outcomes of femoroacetabular impingement syndrome? *Arch Orthop Trauma Surg.* 2023 Oct;143(10):6283-6294. doi: 10.1007/s00402-023-04927-6. Epub 2023 Jun 14. PMID: 37316693.

CONCLUSIVE QUESTION

What clinical examination tests are recommended in physically active adults with hip and groin pain?

Statement:

Clinical examination of patients with hip and groin pain needs to be interpreted in conjunction with medical history and imaging studies and/or diagnostic injections where appropriate to make a diagnosis.

A systematic clinical examination of the hip and groin should be performed in all cases. Following assessment of gait and Trendelenburg test, palpation and resistance testing of the adductors, iliopsoas, inguinal canal, and pubic symphysis should be carried out. The hip joint should be evaluated by assessment of range of movement and the FADIR test.

If there is recognizable groin pain on muscle resistance testing that can also be reproduced on palpation of that muscle/tendon, then extra articular muscle/tendons are a likely source. If hip joint ROM and the FADIR test are pain free, then hip joint related groin pain is unlikely. Conversely, if hip joint ROM testing and the FADIR test are painful, the hip should be considered as a possible cause of groin pain.

Regarding hip instability, none of the frequently recommended tests have a high specificity. The consensus group recommends to always consider rotational and/or version abnormalities of the femur and/or tibia and therefore range of movement of the hip should be performed in the prone position as well.

When young and active individuals present with groin pain it is important not to neglect the possibility of serious pathology (red flags). Especially if the clinical presentation does not fit with a common clinical entity like adductor, inguinal, iliopsoas, pubic or hip related groin pain. It is common for a single patient to have pain arising from multiple clinical entities.

Grade of recommendation: C

Agreement : median 9 (6-9)

ADDITIONAL USEFUL INFORMATION

During the diagnostic clinical reasoning process of a patient reporting groin pain, other useful information should be considered aside specific clinical tests. See the following sections.

Subjective Assessment

- *Location of pain: The location of pain gives information regarding the structures potentially involved in the injury and should be included in the subjective assessment.*
- *Injury mechanism: the mechanisms of injury can assist the clinician in the diagnostic process. High speed movements at long muscle length such as change of direction, kicking, reaching, and jumping are the common actions associated with acute groin injuries [15].*
- *Onset of pain: Different structures develop pain in different ways. Knowing the evolution of pain in time is a valuable information to collect during the patient subjective examination.*
- *Systemic symptoms: important red flags such as unexplained weight loss, fatigue, fever, painful urination and night pain should be immediately recognised and referred to a specialist for further investigations [17].*

Patient Reported Outcome Measures

The Copenhagen Hip and Groin Outcome Score (HAGOS) and iHot-12 have adequate measurement qualities for the assessment of symptoms, activity limitations, participation restrictions and quality of life in physically active, young to middle-aged patients with longstanding hip and/or groin pain and is recommended for use in interventions where the patient's perspective and health-related quality of life are of primary interest.

Literature summary:

Level of Evidence	Studies
I	Nil
II	[6, 10, 11, 16]
III	[3, 9, 15, 17]
IV	[8, 12–14]
V	[2, 4, 5, 18, 19]

Adductor-related groin pain

- **Symptoms:** Pain around the insertion of the adductor longus tendon at the pubic bone. Pain may radiate distally along the medial thigh [7, 19].
- **Clinical tests:** Adductor tenderness at palpation (patient reports discomfort or pain when the area is palpated, and recognises this to be the specific injury pain) AND pain on resisted adduction testing [19]:
 - **Adductor palpation test** (*intra-rater k= 0.89 and inter-rater k= 0.94[6]*): The subject lies supine. The leg to be tested is placed on a pillow with the hip flexed, abducted, and externally rotated, and the knee slightly flexed. The leg must be relaxed in this position. The subject is instructed to register pain and ignore the

natural soreness present in this area. The examiner palpates with two fingers the adductor longus tendon and follows the tendon to the insertion at the pubic bone. The insertion area, including the bone, is tested with firm pressure in a radius of about 1 cm. Pain is recorded as “yes” or “no” [6].

- **Resisted adduction testing** (*intra-rater k= 0.91 and inter-rater k= 0.92*[6]): Different tests have been suggested in the literature for the adductor compartment: a) isometric squeeze test with proximal (at knee level) resistance; b) isometric squeeze test with distal resistance (at ankles level), c) isometric squeeze test with distal resistance and abducted legs, isometric squeeze test with flexed knee and proximal resistance, d) isometric squeeze test performed separately with the two legs with the use of a dynamometer[2]. The squeeze-0° test has been shown to be a superior test to other angles (45° and 90°) for pain provocation induced in the adductor region [3]. Pain is recorded as “yes” or “no” [6].

Iliopsoas-related groin pain

- **Symptoms:** Pain in the anterior part of the proximal thigh, more laterally located than adductor-related groin pain [18, 19].
- **Clinical tests:** The group agreed that iliopsoas-related groin pain is more likely if there is pain on resisted hip flexion AND/OR pain on stretching the hip flexors [19]:
 - **Resisted hip flexion test** (*intra-rater k= 0.32 and inter-rater k= 0.64*[6]): The subject lies supine. The test leg is flexed maximally in the hip and knee joint. The examiner tries to extend the flexed hip by pulling it with one arm wrapped around the femur just proximal to the knee. Pain is recorded as “yes” or “no” [6].
 - **Hip flexor stretch (modified Thomas test)** (*intra-rater k= 0.81 and inter-rater k= 0.85*[6]): The subject lies supine with legs hanging from the end of the couch. The subject then flexes one hip by clasping the knee in both hands and pulling it down to his chest. The other leg is hanging relaxed from the end of the couch. At the same time, the patient lifts head and shoulders as far as possible. The examiner stands at the end of the couch supporting the position by pressing the side of his/her trunk against the foot of the flexed leg. Pain is recorded as “yes” or “no” [6].
 - **Iliopsoas Palpation (pain provocation test)** (*intra-rater k = 0.84, inter-rater k = 0.81*): The psoas pain on palpation test is performed with the patient supine, and the examiner placing their hands over the lower lateral abdomen at the level of the iliac spine. The iliopsoas muscle is palpated lateral to the edge of the rectus abdominus muscle, and once it is palpated, the subject is asked to elevate the foot 10cm while the psoas is deeply palpated. Pain is recorded as “yes” or “no” [6].

Inguinal-related groin pain

- **Symptoms:** Pain in the inguinal region that worsens with activity. If pain is severe, often inguinal pain occurs when coughing or sneezing or sitting up in bed [18, 19].
- **Clinical tests:** Pain location in the inguinal canal region AND tenderness of the inguinal canal. No palpable inguinal hernia is present. Pain is aggravated with resistance testing of the abdominal muscles OR on Valsalva/cough/sneeze [19]:

There is no gold standard for the classification of inguinal-related groin pain, nor an accepted reference standard [5]. The suggested tests are:

- **Abdominal palpation:** (*inter-examiner reliability of the individual inguinal palpation pain provocation tests was fair to moderate ($k=0.35-0.49$), while for the clustered palpation tests (i.e., 'any' inguinal palpation pain) moderate to substantial ($k=0.54-0.65$) [5]). Heijboer et al. recommend using full abdominal palpation (rectus abdominis muscle/insertion, pubic tubercle, inguinal ligament and external ring (medial border)), including scrotal investigation (external ring, conjoint tendon, posterior wall palpation and bulging/valsalva) for the investigation of athletes with inguinal-related groin pain [5].*
- **Abdominal test** (*abdominal resistance test, intra-rater $k= 0.63$ and inter-rater $k= 0.57$ [6] / $k=0.35-0.72$ [5]): Different tests have been suggested in the literature for the abdominal group: a) rectus abdominis eccentric and isometric test, b) sit-up pain test, c) obliquus abdominis eccentric and isometric test [2, 19]. Pain is recorded as "yes" or "no" [6]. Abdominal resistance tests have been reported to be positive in 21%–49% (49% for the cross-test, suggested implementation) of athletes classified with defined inguinal-related groin pain [5].*

Pubic-related groin pain

- **Symptoms:** Pain in the region of the symphysis joint and the immediately adjacent bone [18, 19]
- **Clinical tests:** Local tenderness of the pubic symphysis and the immediately adjacent bone. The group felt that there was no particular resistance test that specifically provoked symptoms related to pubic-related groin pain that could be used in conjunction with palpation [19]
 - **Pubic symphysis palpation** (*intra-rater $k= 0.84$ and inter-rater $k= 0.70$ [6]): The subject lies supine. The symphysis joint is located using gentle palpation with the index finger. The joint is then tested with firm pressure of the index finger tip in the anterior-posterior direction*

Hip-related groin pain

The hip joint should always be assessed during the examination of athletes reporting groin pain.

- **Clinical tests:** Clinicians should keep in mind that, in general, the clinical tests used for the assessment of the hip joint have good sensitivity and low specificity, making them more suited to rule out hip related groin pain [10, 13, 19]. Different tests have been suggested in the literature to assess the hip joint: a) hip joint internal and external rotation measurement, b) Flexion Abduction External Rotation (FABER) test, c) Flexion Adduction Internal Rotation (FADIR) test, d) dynamic internal rotatory impingement test (DIRIT), e) dynamic external rotatory impingement test (DEXTRIT), f) posterior rim impingement test, g) lateral rim impingement test.
 - **Intra articular conditions:**
 - FABER (pain): SN 42-81%, SP 18-75%, LR- 0.72-0.73, LR+ 1.1-2.2 [13]
 - Scour Test (pain): SN 50%, SP 29%, LR- 0.7, LR+ 1.72 [8]
 - Thomas Test (pain and reduced ROM): SN 89, SP 92, LR- 0.12, LR+ 11.1 [9]
 - **Labral Tear/FAI:**
 - FADIR vs magnetic resonance arthrogram (pain): SN 56-100% (most studies > 95%), SP 2-75% (most studies < 25%), LR- 0.22 to 0.76, LR+ 1.02 to 3.3 [12, 13]
 - FADIR vs arthroscopy (pain): SN 97-99%, SP 3-13%, LR- 0.09 to 0.23, LR+ 1.06 to 1.1 [12, 13]
 - Flexion internal rotation (pain): SN 96, SP 25, LR- 0.27, LR+ 1.12 [13]
 - History, painful clicking in the hip: SN 100, SP 85, LR- 0, LR+ 6.7 [11]

References:

1. Altman DG (1990) Practical Statistics for Medical Research. Practical Statistics for Medical Research
2. Bisciotti GN, Volpi P, Zini R, Auci A, Aprato A, Belli A, Bellistri G, Benelli P, Bona S, Bonaiuti D, Carimati G, Canata GL, Cassaghi G, Cerulli S, Delle Rose G, Di Benedetto P, Di Marzo F, Di Pietto F, Felicioni L, Ferrario L, Foglia A, Galli M, Gervasi E, Gia L, Giammattei C, Guglielmi A, Marioni A, Moretti B, Nicolai R, Orgiani N, Pantalone A, Parra F, Quaglia A, Respizzi F, Ricciotti L, Pereira Ruiz MT, Russo A, Sebastiani E, Tancredi G, Tosi F, Vuckovic Z (2016) Groin pain syndrome Italian consensus conference on terminology, clinical evaluation and imaging assessment in groin pain in athlete. *BMJ Open Sport Exerc Med* DOI: 10.1136/bmjsem-2016-000142
3. Drew MK, Palsson TS, Izumi M, Hirata RP, Lovell G, Chiarelli P, Osmotherly PG, Graven-Nielsen T (2016) Resisted adduction in hip neutral is a superior provocation test to assess adductor longus pain: An experimental pain study. *Scand J Med Sci Sports* DOI: 10.1111/sms.12529
4. Griffin DR, Dickenson EJ, O'Donnell J, Agricola R, Awan T, Beck M, Clohisy JC, Dijkstra HP, Falvey E, Gimpel M, Hinman RS, Hölmich P, Kassarian A, Martin HD, Martin R, Mather RC, Philippon MJ, Reiman MP, Takla A, Thorborg K, Walker S, Weir A, Bennell KL (2016) The Warwick Agreement on femoroacetabular impingement syndrome (FAI syndrome): An international consensus statement. *Br J Sports Med* DOI: 10.1136/bjsports-2016-096743
5. Heijboer WMP, Vuckovic Z, Weir A, Tol JL, Hölmich P, Serner A (2023) Clinical examination for athletes with inguinal-related groin pain: interexaminer reliability and prevalence of positive tests. *BMJ Open Sport Exerc Med* DOI: 10.1136/bmjsem-2022-001498

6. Hölmich P, Hölmich LR, Bjerg AM (2004) Clinical examination of athletes with groin pain: An intraobserver and interobserver reliability study. *Br J Sports Med* DOI: 10.1136/bjism.2003.004754
7. Landis JR, Koch GG (1977) The measurement of observer agreement for categorical data. *Biometrics* 33(1):159–74
8. Maslowski E, Sullivan W, Forster Harwood J, Gonzalez P, Kaufman M, Vidal A, Akuthota V (2010) The Diagnostic Validity of Hip Provocation Maneuvers to Detect Intra-Articular Hip Pathology. *PM and R* 2(3):174–181
9. McCarthy JC, Busconi B (1995) The role of hip arthroscopy in the diagnosis and treatment of hip disease. *Orthopedics* DOI: 10.3928/0147-7447-19950801-12
10. Mosler AB, Agricola R, Weir A, Hölmich P, Crossley KM (2015) Which factors differentiate athletes with hip/groin pain from those without? A systematic review with meta-analysis. *Br J Sports Med*
11. Narvani AA, Tsiridis E, Kendall S, Chaudhuri R, Thomas P (2003) A preliminary report on prevalence of acetabular labrum tears in sports patients with groin pain. *Knee Surgery, Sports Traumatology, Arthroscopy* DOI: 10.1007/s00167-003-0390-7
12. Reiman MP, Goode AP, Cook CE, Hölmich P, Thorborg K (2015) Diagnostic accuracy of clinical tests for the diagnosis of hip femoroacetabular impingement/labral tear: A systematic review with meta-analysis. *Br J Sports Med*
13. Reiman MP, Goode AP, Hegedus EJ, Cook CE, Wright AA (2013) Diagnostic accuracy of clinical tests of the hip: A systematic review with meta-analysis. *Br J Sports Med*
14. Serner A, Van Eijck CH, Beumer BR, Hölmich P, Weir A, DeVos RJ (2015) Study quality on groin injury management remains low: A systematic review on treatment of groin pain in athletes. *Br J Sports Med*
15. Serner A, Mosler AB, Tol JL, Bahr R, Weir A (2019) Mechanisms of acute adductor longus injuries in male football players: A systematic visual video analysis. *Br J Sports Med* DOI: 10.1136/bjsports-2018-099246
16. Serner A, Weir A, Tol JL, Thorborg K, Roemer F, Guermazi A, Hölmich P (2016) Can standardised clinical examination of athletes with acute groin injuries predict the presence and location of MRI findings? *Br J Sports Med* DOI: 10.1136/bjsports-2016-096290
17. Thorborg K, Hölmich P, Christensen R, Petersen J, Roos EM (2011) The Copenhagen Hip and Groin Outcome Score (HAGOS): Development and validation according to the COSMIN checklist. *Br J Sports Med* DOI: 10.1136/bjism.2010.080937
18. Thorborg K, Reiman MP, Weir A, Kemp JL, Serner A, Mosler AB, Hölmich P (2018) Clinical examination, diagnostic imaging, and testing of athletes with groin pain: An evidence-based approach to effective management. *Journal of Orthopaedic and Sports Physical Therapy*
19. Weir A, Brukner P, Delahunt E, Ekstrand J, Griffin D, Khan KM, Lovell G, Meyers WC, Muschaweck U, Orchard J, Paajanen H, Philippon M, Rebol G, Robinson P, Schache AG, Schilders E, Serner A, Silvers H, Thorborg K, Tyler T, Verrall G, De Vos RJ, Vuckovic Z, Hölmich P (2015) Doha agreement meeting on terminology and definitions in groin pain in athletes. *Br J Sports Med*

III Imaging

The aim of this section is to reach consensus upon recommendations for performing imaging on physically active adults with hip and groin pain.

Introduction

Interobserver and intraobserver reliability of imaging tests of the hip and groin

Several studies showed good to almost perfect interobserver reliability for measuring the CE angle; intraclass coefficient (ICC, κ) varied between 0.73 and 0.96. Using the CE angle $\geq 40^\circ$ is a reasonably good predictor of pincer FAI, with a sensitivity of 84% and a specificity of 100%. The reliability of the crossover sign is more variable. Kappa values have been reported between 0.51 and 0.70 for the inter-observer reliability.

Anteroposterior radiographs have poor sensitivity compared with CT and MRI (57% and 27%, respectively) and are influenced by the pelvic tilt.

The reliability of radiographic diagnosis of structural hip abnormalities is limited. For the radiographic assessment of various structural features around the hip, intraobserver and interobserver reliability in the young adult hip range between ICCs of 0.30 (95% CI: 0.23–0.37) and 0.73 (95% CI: 0.68–0.79) for the former, and of 0.19 and 0.64 for the latter. In terms of reaching a radiographic diagnosis, this translates to an intraobserver reliability of between $\kappa = 0.56$ (95% CI: 0.48–0.65) and $\kappa = 0.82$ (95% CI: 0.77–0.88), and interobserver reliability of $\kappa = 0.46$ and $\kappa = 0.80$.

Radiation dose and associated risk for radiography and CT scans

The effective ionizing radiation doses from CT are estimated to range between 1 and 10 mSv [<https://www.fda.gov>]. The risk of developing cancer because of exposure to ionizing radiation depends on the part of the body exposed, the age at exposure, and the sex. Exposure to diagnostic radiation below the waist may increase testicular germ cell tumour risk. According to the U.S. Food and Drug Administration, a CT examination with an effective dose of 10 mSv (1 mSv = 1 mGy in the case of radiographs) may be associated with an increase in the possibility of fatal cancer of approximately 1 chance in 2,000. When this increase in the possibility of a fatal cancer from radiation is compared to the natural incidence of fatal cancer in the U.S. population, which is about 1 chance in 5 (equal to 400 chances in 2,000), for any one person the risk of radiation-induced cancer is much smaller than the natural risk of cancer. The combination of the natural risk of a fatal cancer and the estimated risk from a 10 mSv CT scan might increase the total risk from 400 chances in 2,000 to 401 chances in 2,000.

Protocols with CT scans of the hip/pelvis pose a small lifetime attributable risk (0.034%–0.177% for a 20-year-old) but a large relative risk (5–17 times) of cancer compared with radiographs alone in the imaging evaluation for hip pain (the risk decreases with increasing age).

Although ionizing radiation dose varies across patients and scanners, dual-energy CT scans allow for comparable and potentially decreased dose in comparison to single-energy CT.

QUESTION 1

Are imaging examinations of the hip joint able to differentiate between those with and without symptoms?

Statement:

Imaging examinations are not able to differentiate between those with or without symptoms. There is uncertainty of the relationship between intraarticular hip joint morphology/pathology on imaging and groin pain.

There is evidence to support the association of patient reported pain with cam morphology (proportional to alpha angle), mixed FAI morphology, articular cartilage pathology, ligamentum teres tears and bone marrow oedema. Current evidence does not show an association between patient-reported pain and isolated pincer morphology.

A major limitation of the imaging studies is that the dynamic, mechanical nature of the hip impingement or instability as well as that of groin pain etiology is still being examined mostly by static means that either only reveal the anatomical risk factors which may be responsible for symptoms or an underlying lesion that is not necessarily symptomatic.

For asymptomatic individuals routine imaging screening of the hip joint is not warranted. Individuals with risk factors for FAIS and/or acetabular dysplasia such as a family history of hip disease and/or decreased internal rotation of the hip on clinical examination may benefit from counseling regarding physical activities.

Grade of recommendation: C

Agreement : median 8 (1-9)

Literature summary:

If MRI, CT or US were able to differentiate between subjects with and without symptoms it would have meant that there would be a high association between pain (or lack of it) and imaging. It would also mean that imaging can be used as a prognostic tool for high-risk individuals that could be screened prior to developing (or already with minor) symptoms.

In an interesting paper, the authors looked at hips of 45 asymptomatic volunteers with an average age of 38 years (range, 15–66 years); 60% were men. (1) The volunteers underwent a unilateral 3.0T MRI examination. Labral tears were identified in 69% of hips, chondral defects in 24%, ligamentum teres tears in 2%, labral or paralabral cysts in 13%, acetabular bone marrow oedema in 11%, fibrocystic changes of the femoral head and neck junction in 22%, acetabular rim fractures in 11%, subchondral cysts in 16%, and osseous bumps in 20%. Participants older than 35 years were 13.7 times (95% CI, 2.4–80 times) more likely to have a chondral defect and 16.7 times (95% CI, 1.8–158 times) more likely to have a subchondral cyst

compared with participants 35 years of age or younger. Cartilage defects and subchondral cysts were considered as early markers of cartilage degeneration. No other joint lesions were associated with age. Male subjects were 8.5 times (95% CI, 1.2–56 times) more likely to have an osseous bump than females. No other joint lesions were associated with sex.

There are other studies that support similar common findings of FAI morphologic features (i.e., cam and/or pincer) and labral pathology in asymptomatic patients including subgroups such as high-level athletes. (2, 3, 4) The observation that FAI morphology seems to be prevalent in asymptomatic athletes just amplifies the fact that we should carefully analyze the association of patient history and physical examination with imaging. (5)

Mosler et al. tried to link the association between intrinsic risk factors identified from musculoskeletal and radiographic screening tests and hip or groin injuries in professional male soccer players. They concluded that these associations were not strong enough to identify an "at-risk" individual, and, therefore, musculoskeletal screening tests were not useful to dictate individualized prevention strategies. Bony hip morphology was not associated with the risk of groin injuries. (6)

Trying to link prevalence rates for cam, pincer, and mixed FAI, particularly among such distinct populations as asymptomatic or symptomatic subjects and athletes, Mascarenhas et al. in a systematic review reported that cam morphology was significantly more common in symptomatic versus asymptomatic cases ($p=0.009$). (7) The percentage of patients with cam FAI morphology showed significant differences across groups ($p=0.006$). No significant differences were found between pincer morphology prevalence when comparing athletes to symptomatic patients. However, mixed FAI morphology was significantly more common in athletes versus asymptomatic subjects ($p=0.03$) and in asymptomatic versus symptomatic subjects ($p=0.015$). The mean alpha angle was significantly greater in the symptomatic group versus either the asymptomatic or athlete group ($p<0.001$). The authors concluded that imaging suspicion of FAI is common among athletes, asymptomatic, and symptomatic populations; however, significant differences in types and imaging signs of FAI morphology exist among these groups that need to be considered in decision making (7).

The paper that came closer to answer the initial question was a recent meta-analysis by Heerey et al. who looked at the prevalence of imaging-defined intraarticular hip pathology in people with and without pain. (8) The authors identified 29 studies that used MRI, MRA and/or CT as imaging in correlation with symptoms. They noted that the prevalence of cartilage pathology is higher in people with pain than those without. Similarly, bone marrow lesions and ligamentum teres tears appear to be associated with individuals that report pain. In contrast, the prevalence of labral pathology, paralabral cysts and synovial herniation pits are similar in those with and without pain. This review highlights the uncertainty of the relationship between intraarticular hip joint pathology on imaging and pain.

In a unique paper, Anderson et al. reported the prevalence of hip dysplasia and FAI morphology in a group of highly functional senior athletes. (9) A total of 1081 hips in 547 individuals of an average age of 67 years were included in this cohort. The authors found that

83% (898 of 1081) of hips had radiographic abnormalities consistent with FAI; of those hips, 67% had cam morphology and 10% (103 of 1081) had radiographic evidence of dysplasia. Although other studies have looked at the prevalence of hip deformities in the general population, this study concentrated on hips that have not only remained asymptomatic, but also remained healthy enough to allow participation in sports. Even though after controlling for age and sex, neither radiographic signs of FAI morphology nor dysplasia were predictive of OA in this select asymptomatic population of senior athletes, we cannot conclude that dysplasia and FAIS are not associated with the development of OA overall (since such lack of association might be the case only in this active senior population). These data suggest that screening asymptomatic young athletes for radiographic evidence of FAI and developmental dysplasia of the hip may not be necessary. Perhaps the most interesting question that is raised by this study is: What are the other nonanatomic protective factors that have allowed these senior hips to flourish despite the presence of radiographic risk factors, and indeed in 17% of participants, the occurrence of actual osteoarthritis?

References:

1. Register B, Pennock AT, Ho CP, Strickland CD, Lawand A, Philippon MJ. Prevalence of Abnormal Hip Findings in Asymptomatic Participants: A Prospective, Blinded Study. *Am J Sports Med.* 2012;40(12):2720-2724.
2. Kapron AL, Anderson AE, Aoki SK, Phillips LG, Petron DJ, Toth R, Peters CL. Radiographic prevalence of femoroacetabular impingement in collegiate football players: AAOS Exhibit Selection. *J Bone Joint Surg Am.* 2011 Oct 5;93(19):e111(1-10).
3. Frank JM, Harris JD, Erickson BJ, Slikker W 3rd, Bush-Joseph CA, Salata MJ, Nho SJ. Prevalence of Femoroacetabular Impingement Imaging Findings in Asymptomatic Volunteers: A Systematic Review. *Arthroscopy.* 2015 Jun;31(6):1199-204.
4. Na Kim J, Jin Park H, Yeon Won S, Kim M, Woo Hong S, Kim E, Jin Park S, Taek Lee Y. Whole-body MRI for preventive health screening in a general population: Prevalence of incidental findings around the hip. *Eur J Radiol.* 2022 May;150:110239.
5. Reiman MP, Thorborg K, Goode AP, Cook CE, Weir A, Hölmich P. Diagnostic Accuracy of Imaging Modalities and Injection Techniques for the Diagnosis of Femoroacetabular Impingement/Labral Tear: A Systematic Review With Meta-analysis. *Am J Sports Med.* 2017 Sep;45(11):2665-2677.
6. Mosler AB, Weir A, Serner A, Agricola R, Eirale C, Farooq A, Bakken A, Thorborg K, Whiteley RJ, Hölmich P, Bahr R, Crossley KM. Musculoskeletal Screening Tests and Bony Hip Morphology Cannot Identify Male Professional Soccer Players at Risk of Groin Injuries: A 2-Year Prospective Cohort Study. *Am J Sports Med.* 2018 May;46(6):1294-1305
7. Mascarenhas VV, Rego P, Dantas P, Morais F, McWilliams J, Collado D, Marques H, Gaspar A, Soldado F, Consciência JG. Imaging prevalence of femoroacetabular impingement in symptomatic patients, athletes, and asymptomatic individuals: A systematic review. *Eur J Radiol.* 2016 Jan;85(1):73-95.
8. Heerey JJ, Kemp JL, Mosler AB, Jones DM, Pizzari T, Souza RB, Crossley KM. What is the prevalence of imaging-defined intra-articular hip pathologies in people with and without pain? A systematic review and meta-analysis. *Br J Sports Med.* 2018 May;52(9):581-593.
9. Anderson LA, Anderson MB, Kapron A, Aoki SK, Erickson JA, Chrastil J, Grijalva R, Peters C. The 2015 Frank Stinchfield Award: Radiographic Abnormalities Common in Senior Athletes With Well-functioning Hips but Not Associated With Osteoarthritis. *Clin Orthop Relat Res.* 2016 Feb;474(2):342-52.

QUESTION 2

How are imaging examinations of the hip used to identify and measure cam and pincer morphology and acetabular coverage?

Statement:

Imaging (radiographs, MRI or CT) makes it possible to quantitatively assess the hip joint morphology and to identify cam or pincer morphology, acetabular dysplasia, as well as femoral and acetabular rotational profile. Whilst clear cut-off values are recommended, all measurements are subject to error.

Cam morphology

Anteroposterior radiographs and Dunn 45 views or similar lateral views should be assessed for the alpha angle and/or the femoral offset. Cam morphology is present if the alpha angle is $>60^\circ$. Radial MRI or CT is more sensitive than radiographs for diagnosing cam morphology. 3D CT is optimal for preoperative planning. Femoral torsion also has a bearing on symptomatic cam impingement, regardless of the morphology at the hip and is assessed by acquiring axial images through the femoral condyle during CT/MRI scanning.

Pincer morphology

Pincer morphology should be evaluated on AP radiographs (that feature a 2.5-cm distance between the pubic symphysis and the sacrococcygeal junction) assessing the lateral centre-edge (LCE) angle, crossover sign, posterior wall sign, ischial spine sign and acetabular index. Pincer morphology is suspected if the LCE angle $>40^\circ$, or in the presence of a crossover sign, posterior wall sign or ischial spine sign. Of these, the LCE angle is the most reliable.

Acetabular dysplasia

Acetabular dysplasia should be assessed on AP radiographs by measuring the LCE angle and acetabular index. Acetabular dysplasia is present if LCEA $<20^\circ$ or LCEA is $20^\circ-25^\circ$ (borderline dysplasia) and/or the acetabular index is $>10^\circ$. In measuring LCEA, the lateral cut-off point to be taken into consideration is the end of the lateral sourcil as stated by Wiberg and not the lateral acetabular rim.

Rotational Profile

While the rotational profile of the femur and acetabulum is less studied, it has been suggested that deviations from normal ranges could contribute to symptom expression and potentially exacerbate/enhance co-existing findings (i.e. cam or pincer). For this reason and

to gain a better understanding of the rotational profile of the femur and acetabulum, it is suggested to measure the femoral and acetabular version, especially when rotational abnormalities are suspected on clinical examination e.g. hips with femoral anteversion and acetabular anteversion exhibit an increase in internal rotation range of movement at a neutral hip position (mean - 44.2°), whereas hips with femoral retroversion and acetabular retroversion demonstrate a decrease in internal rotation (20.1°).

Radiographic femoral and acetabular rotational profiles can be assessed using a CT scan which includes (in addition to the hip joint assessment) axial images of the distal femur.

Radiography is less reliable than CT or MRI for evaluating acetabular morphology and acetabular and femoral version.

Grade of recommendation: C

Agreement : median 8 (7-9)

Literature Summary:

Cam morphology

Cam morphology is defined as an osseous or cartilage or bony prominence (bump) of varying size at the femoral head–neck junction, which changes the shape of the femoral head from spherical to aspherical [Dijkstra 2021]. The alpha angle is considered the main measurable outcome and was originally described on axial oblique images on MRI [Notzli 2002]. The alpha angle is considered abnormal if above 60°. If cam morphology is present at the 1–2-o’clock position, patients have a higher chance of having symptoms [Agricola 2014; Mascarenhas 2020; van Klij 2020].

The aspherical portion of the proximal femur and osseous bump is typically most prominent anterior superiorly. Assessment of cam morphology requires an AP pelvic radiograph as well the Dunn view (45° hip flexion, 20° abduction and neutral rotation) or similar lateral views [Mascarenhas 2020].

Sensitivity varies from 71% to 96% with a specificity of 36% to 90 % for detecting cam morphology on radiographs [Barton 2011, Domayer 2011, Nepple 2012, Saito 2017, Yamamoto 2014]. It is important to note that 35% of cam morphology can be missed on radiographs as they were only performed in two projections [Dudda 2009]. The interobserver reliability of detecting a cam morphology was good to almost perfect with an ICC between 0.83 and 0.97 [Domayer 2011; Gosvig 2007; Mast 2011].

Femoral offset (FO) is another parameter to assess the femoral head–neck junction. It describes the width of the femoral neck relative to the femoral head. FO is abnormal if less

than 8 mm (also a ratio between the anterior offset and the diameter of the head <0.13 indicates cam morphology [Ehrmann et al., 2015; Tannast et al., 2007]).

References:

1. Dijkstra HP, Ardern CL, Serner A, Mosler AB, Weir A, Roberts NW, et al. Primary cam morphology; bump, burden or bog-standard? A concept analysis. *Br J Sports Med.* 2021;55(21):1212-21.
2. Notzli HP, Wyss TF, Stoecklin CH, Schmid MR, Treiber K, Hodler J. The contour of the femoral head-neck junction as a predictor for the risk of anterior impingement. *J Bone Joint Surg Br.* 2002;84(4):556-60.
3. Agricola R, Waarsing JH, Thomas GE, Carr AJ, Reijman M, Bierma-Zeinstra SM, et al. Cam impingement: defining the presence of a cam deformity by the alpha angle: data from the CHECK cohort and Chingford cohort. *Osteoarthritis Cartilage.* 2014;22(2):218-25.
4. Mascarenhas VV, Castro MO, Rego PA, Sutter R, Sconfienza LM, Kassarian A, et al. The Lisbon Agreement on Femoroacetabular Impingement Imaging-part 1: overview. *Eur Radiol.* 2020;30(10):5281-97.
5. van Klij P, Reiman MP, Waarsing JH, Reijman M, Bramer WM, Verhaar JAN, et al. Classifying Cam Morphology by the Alpha Angle: A Systematic Review on Threshold Values. *Orthop J Sports Med.* 2020;8(8):2325967120938312.
6. Barton C, Salineros MJ, Rakhra KS, Beaulé PE. Validity of the alpha angle measurement on plain radiographs in the evaluation of cam-type femoroacetabular impingement. *Clin Orthop Relat Res.* 2011;469(2):464-9.
7. Domayer SE, Ziebarth K, Chan J, Bixby S, Mamisch TC, Kim YJ. Femoroacetabular cam-type impingement: diagnostic sensitivity and specificity of radiographic views compared to radial MRI. *Eur J Radiol.* 2011;80(3):805-10.
8. Nepple JJ, Martel JM, Kim YJ, Zaltz I, Clohisy JC, Group AS. Do plain radiographs correlate with CT for imaging of cam-type femoroacetabular impingement? *Clin Orthop Relat Res.* 2012;470(12):3313-20.
9. Saito M, Tsukada S, Yoshida K, Okada Y, Tasaki A. Correlation of alpha angle between various radiographic projections and radial magnetic resonance imaging for cam deformity in femoral head-neck junction. *Knee Surg Sports Traumatol Arthrosc.* 2017;25(1):77-83.
10. Yamamoto Y, Hiejima Y. Usefulness of cross-table lateral view radiograph for the diagnosis of cam-type femoroacetabular impingement. *Eur J Orthop Surg Traumatol.* 2014;24(3):365-9.
11. Dudda M, Albers C, Mamisch TC, Werlen S, Beck M. Do normal radiographs exclude asphericity of the femoral head-neck junction? *Clin Orthop Relat Res.* 2009;467(3):651-9.
12. Gosvig KK, Jacobsen S, Palm H, Sonne-Holm S, Magnusson E. A new radiological index for assessing asphericity of the femoral head in cam impingement. *J Bone Joint Surg Br.* 2007;89(10):1309-16.
13. Mast NH, Impellizzeri F, Keller S, Leunig M. Reliability and agreement of measures used in radiographic evaluation of the adult hip. *Clin Orthop Relat Res.* 2011;469(1):188-99.
14. Ehrmann C, Roskopf AB, Pfirrmann CW, Sutter R. Beyond the alpha angle: Alternative measurements for quantifying cam-type deformities in femoroacetabular impingement. *J Magn Reson Imaging.* 2015;42(4):1024-31.
15. Tannast M, Siebenrock KA, Anderson SE. Femoroacetabular impingement: radiographic diagnosis—what the radiologist should know. *AJR Am J Roentgenol.* 2007;188(6):1540-52.

Pincer morphology or acetabular dysplasia

Pincer morphology is defined as focal or global overcoverage of the acetabulum [Ganz 2003, Griffin 2016]. There can be increased acetabular coverage or retroversion. Commonly used radiographic markers for pincer morphology are:

- 1: Crossover sign (contour of the anterior wall intersects and becomes lateral to the contour of the posterior wall)
- 2: Lateral center-edge (CE) angle (angle measured between two lines drawn from the center of the circle, one running vertically along the longitudinal axis of the pelvis and the other to the lateral acetabular rim)
- 3: Posterior wall sign (projection of the posterior acetabular wall is medial to the projection of the femoral head center)
- 4: Ischial spine sign (projected triangular shape of the ischial line protrudes, and is visible medially to the pelvic brim)
- 5: Acetabular index (Tonnis angle formed between a horizontal line at level of medial edge of sourcil and line tangential to medial and lateral edges of sourcil).

The most commonly used signs are crossover sign, lateral CE angle and posterior wall sign [Rhee 2017]. Overcoverage or pincer morphology is defined as CE angle $>40^\circ$. Undercoverage (acetabular dysplasia) is defined as a CE angle $<20^\circ$ and borderline undercoverage $20^\circ-25^\circ$ [Mascarenhas 2020, Rhee 2017, Tannast 2015, Tannast 2007]. Acetabular dysplasia is present if the CE is $<20^\circ$ or CE is $20^\circ-25^\circ$ (borderline dysplasia) and/or acetabular index $>10^\circ$ [Wilkin 2017]

Several studies showed good to almost perfect interobserver reliability for measuring the CE angle; ICC varied between $K = 0.73$ and $K = 0.96$ [Kutty 2012, Mast 2011, Nelitz 1999, Tannast 2008]. Using the CE angle ≥ 40 is a reasonably good predictor of FAI, with a sensitivity of 84% and a specificity of 100% [Kutty 2012]. In this retrospective study, 55 patients with FAI syndrome, of which 19 patients had a pincer morphology, were compared to a control group of 30 patients selected from the emergency department with similar age. Surgery was the reference standard. The CE angle was significantly higher in the FAI group than in the control group with excellent interobserver reliability.

The reliability of the crossover sign was more variable. Kappa value have been reported between 0.51 and 0.70 for the interobserver reliability [Jamali 2007, Kappe 2011, Mast 2011, Tannast 2008]. Anteroposterior radiographs have poor sensitivity compared with CT and MRI (57% and 27%, respectively) and are influenced by the pelvic tilt [Bellaiche 2010, Wassilew 2012].

Although rare in youth athletes, protrusio acetabuli (whereby femoral head contour overlaps the ilioischial line) is also a form of pincer morphology.

Developmental dysplasia of the hip should be included in the differential diagnosis and is a common cause of hip pain.

References:

1. Ganz R, Parvizi J, Beck M, Leunig M, Notzli H, Siebenrock KA. Femoroacetabular impingement: a cause for osteoarthritis of the hip. *Clin Orthop Relat Res.* 2003(417) :112-20.
2. Griffin DR, Dickenson EJ, O'Donnell J, Agricola R, Awan T, Beck M, et al. The Warwick Agreement on femoroacetabular impingement syndrome (FAI syndrome): an international consensus statement. *Br J Sports Med.* 2016;50(19):1169-76.
3. Rhee C, Le Francois T, Byrd JWT, Glazebrook M, Wong I. Radiographic Diagnosis of Pincer-Type Femoroacetabular Impingement: A Systematic Review. *Orthop J Sports Med.* 2017;5(5):2325967117708307.
4. Mascarenhas VV, Castro MO, Rego PA, Sutter R, Sconfienza LM, Kassarian A, et al. The Lisbon Agreement on Femoroacetabular Impingement Imaging-part 1: overview. *Eur Radiol* 2020;30(10):5281-97.
5. Tannast M, Hanke MS, Zheng G, Steppacher SD, Siebenrock KA. What are the radiographic reference values for acetabular under- and overcoverage? *Clin Orthop Relat Res.* 2015;473(4):1234-46.
6. Tannast M, Siebenrock KA, Anderson SE. Femoroacetabular impingement: radiographic diagnosis—what the radiologist should know. *AJR Am J Roentgenol.* 2007;188(6):1540-52.
7. Kutty S, Schneider P, Faris P, Kiefer G, Frizzell B, Park R, et al. Reliability and predictability of the centre-edge angle in the assessment of pincer femoroacetabular impingement. *Int Orthop.* 2012;36(3):505-10.
8. Mast NH, Impellizzeri F, Keller S, Leunig M. Reliability and agreement of measures used in radiographic evaluation of the adult hip. *Clin Orthop Relat Res.* 2011;469(1):188-99.
9. Nelitz M, Guenther KP, Gunkel S, Puhl W. Reliability of radiological measurements in the assessment of hip dysplasia in adults. *Br J Radiol.* 1999;72(856):331-4.
10. Tannast M, Mistry S, Steppacher SD, Reichenbach S, Langlotz F, Siebenrock KA, et al. Radiographic analysis of femoroacetabular impingement with Hip2Norm-reliable and validated. *J Orthop Res.* 2008;26(9):1199-205.
11. Jamali AA, Mladenov K, Meyer DC, Martinez A, Beck M, Ganz R, et al. Anteroposterior pelvic radiographs to assess acetabular retroversion: high validity of the “cross-over-sign”. *J Orthop Res.* 2007;25(6):758-65.
12. Kappe T, Kocak T, Neuerburg C, Lippacher S, Bieger R, Reichel H. Reliability of radiographic signs for acetabular retroversion. *Int Orthop.* 2011;35(6):817-21.
13. Bellaiche L, Lequesne M, Gedouin JE, Laude F, Boyer T, French Arthroscopy S. Imaging data in a prospective series of adult hip pain in under 50-year-olds. *Orthop Traumatol Surg Res.* 2010;96(8 Suppl):S44-52.
14. Wassilew GI, Heller MO, Diederichs G, Janz V, Wenzl M, Perka C. Standardized AP radiographs do not provide reliable diagnostic measures for the assessment of acetabular retroversion. *J Orthop Res.* 2012;30(9):1369-76.
15. Wilkin GP, Ibrahim MM, Smit KM, et al. A contemporary definition of hip dysplasia and structural instability: toward a comprehensive classification for acetabular dysplasia. *J Arthroplasty* 2017;32:S20–7.

CT and MRI for detection of cam or pincer morphology

CT and MRI are both superior to radiography in assessing the hip morphology with the possibility of 3D reconstruction. Nevertheless, an underestimation of 17° has been reported on measuring the alpha angle on axial oblique images compared to the maximum alpha angle on radial MR images [Rakhra 2009]. Radial images are considered to be the most accurate way for assessment of the cam morphology, using 12 slices in a clock-like fashion [Klenke 2015, Sutter 2012].

Assessing the CE angle or acetabular index on MRI showed similar results compared to radiography with an ICC of 0.95 and 0.87, respectively [Stelzeneder 2013].

More distally located cam morphology has been described as extraarticular subspinal impingement which is provoked by an exaggerated downsloping of the anterior-inferior iliac spine [Samim 2019].

Dynamic evaluation in CT is promising and shows similar results in detecting FAI morphology [Roling 2020]. Heyworth et al. showed moderate value in predicting mechanically based FAI labral tear patterns with low intraoperative agreement of detecting cam ($K=0.48$) and pincer ($K=0.16$) morphology [Heyworth 2012]. CT is optimal for pre-operative 3D reconstruction and for the measurement of femoral torsion [Wells 2017, Chuang 2023]. More recently, CT-like sequences have been utilized on MRI that are also applicable for assessing and measuring hip and acetabular morphology with results similar to standard CT [Breighner 2019, Florkow 2022, Aydingoz 2022, Morbee 2022].

Femoral Antetorsion: Comparing Asymptomatic Volunteers and Patients with Femoroacetabular Impingement

The role of femoral version on FAIS is an issue that continues to be debated. According to a study published in 2021, up to 51% of patients presenting with FAIS show an abnormal femoral version, whilst up to 31% demonstrate abnormal acetabular version [Arshad 2021]. The authors concluded that this high percentage of version abnormalities highlights the importance of evaluating these parameters routinely during assessment of patients with symptoms of FAIS to guide clinical decision-making. A more recent study identified in a large osteological collection of human femurs a significant positive relationship between the alpha angle and increasing femoral version [Schaver 2022]. On the other hand, in another recent study of a large random sample of cadaveric hips, cam morphology was not associated with femoral or acetabular retroversion [Sinkler 2024].

References:

1. Rakhra KS, Sheikh AM, Allen D, Beaulé PE. Comparison of MRI alpha angle measurement planes in femoroacetabular impingement. *Clin Orthop Relat Res.* 2009;467(3):660-5.
2. Klenke FM, Hoffmann DB, Cross BJ, Siebenrock KA. Validation of a standardized mapping system of the hip joint for radial MRA sequencing. *Skeletal Radiol.* 2015;44(3):339-43.
3. Sutter R, Dietrich TJ, Zingg PO, Pfirrmann CW. How useful is the alpha angle for discriminating between symptomatic patients with cam-type femoroacetabular impingement and asymptomatic volunteers? *Radiology.* 2012 Aug;264(2):514-21. Doi: 10.1148/radiol.12112479.
4. Stelzeneder D, Hingsammer A, Bixby SD, Kim YJ. Can radiographic morphometric parameters for the hip be assessed on MRI? *Clin Orthop Relat Res.* 2013;471(3):989-99.
5. Samim M, Walter W, Gyftopoulos S, Poultsides L, Youm T. MRI Assessment of Subspine Impingement: Features beyond the Anterior Inferior Iliac Spine Morphology. *Radiology.* 2019;293(2):412-21.
6. Wells J, Nepple JJ, Crook K, Ross JR, Bedi A, Schoenecker P, et al. Femoral Morphology in the Dysplastic Hip: Three-dimensional Characterizations With CT. *Clin Orthop Relat Res.* 2017;475(4):1045-54.
7. Heyworth BE, Dolan MM, Nguyen JT, Chen NC, Kelly BT. Preoperative three-dimensional CT predicts intraoperative findings in hip arthroscopy. *Clin Orthop Relat Res.* 2012;470(7):1950-7.
8. Chuang CA, Sheu H, Yang CP, Tang HC, Wu CT, Fu CJ, et al. Combined 3-Dimensional CT and Multidirectional CT Arthrography for Femoroacetabular Impingement and Hip Lesions: A Cross-sectional

- Study Comparing Imaging and Hip Arthroscopic Surgery Findings. *Orthop J Sports Med.* 2023;11(1):23259671221143459.
9. Roling MA, Mathijssen NMC, Bloem RM. Diagnostic sensitivity and specificity of dynamic three-dimensional CT analysis in detection of cam and pincer type femoroacetabular impingement. *BMC Musculoskelet Disord.* 2020;21(1):37.
 10. Breighner RE, Bogner EA, Lee SC, Koff MF, Potter HG. Evaluation of Osseous Morphology of the Hip Using Zero Echo Time Magnetic Resonance Imaging. *Am J Sports Med.* 2019;47(14):3460-8.
 11. Florkow MC, Willemsen K, Zijlstra F, Foppen W, van der Wal BCH, van der Voort van Zyp JRN, et al. MRI-based synthetic CT shows equivalence to conventional CT for the morphological assessment of the hip joint. *J Orthop Res.* 2022;40(4):954-64.
 12. Aydingoz U, Yildiz AE, Ergen FB. Zero Echo Time Musculoskeletal MRI: Technique, Optimization, Applications, and Pitfalls. *Radiographics.* 2022;42(5):1398-414. **Level 4, review.**
 13. Morbee L, Chen M, Van Den Berghe T, Schiettecatte E, Gosselin R, Herregods N, et al. MRI-based synthetic CT of the hip: can it be an alternative to conventional CT in the evaluation of osseous morphology? *Eur Radiol.* 2022;32(5):3112-20
 14. Arshad Z, Maughan HD, Sunil Kumar KH, Pettit M, Arora A, Khanduja V. Over one third of patients with symptomatic femoroacetabular impingement display femoral or acetabular version abnormalities.
 15. *Knee Surg Sports Traumatol Arthrosc.* 2021 Sep;29(9):2825-2836.
 16. Schaver AL, Oshodi A, Glass NA, Duchman KR, Willey MC, Westermann RW. Cam Morphology Is Associated With Increased Femoral Version: Findings From a Collection of 1,321 Cadaveric Femurs. *Arthroscopy.* 2022 Mar;38(3):831-836.
 17. Sinkler MA, Morris WZ, Yuh RT, Fowers CA, Xie K, Cooperman DR, Liu RW. Association of Idiopathic Cam Morphology With Femoral and Acetabular Version: Analysis of 986 Cadaveric Hips. *Orthop J Sports Med.* 2024 Jan 10;12(1):23259671231223185.

Ultrasonography (US)

Although not ideal or often used to assess a cam morphology, US has been studied for detecting cam morphology [Lerch 2013]. Studies by Lerch et al. [2016] and Mandema et al. [2018] showed good correlation between findings on US, radiographs and MRI. No significant difference between the alpha angle on MRI or US could be detected. Interobserver reliability was good with an ICC between 0.74 and 0.98 [Lerch 2016, Mandema 2018].

References:

1. Lerch S, Kasperczyk A, Berndt T, Ruhmann O. Ultrasound is as reliable as plain radiographs in the diagnosis of cam-type femoroacetabular impingement. *Arch Orthop Trauma Surg.* 2016;136(10):1437-43.
2. Mandema L, Tak I, Mooij B, Groeneweg R, Bakker E, van Veldhoven P. Assessment of cam morphology of the hip with ultra sound imaging by physical therapists is reliable and valid. *Phys Ther Sport.* 2018;32:167-72.

Future directions

The next step in detecting and measuring cam morphology and acetabular dysplasia is by the use of machine learning or artificial intelligence (AI). Recently published papers showed good outcomes compared to manually created measurements [Stotter 2023, Archer 2022, Schwarz 2023].

Frysz et al showed using machine learning that cam morphology and acetabular dysplasia were features of severe hip osteoarthritis, but unrelated to moderate disease [2022].

AI is a promising tool in the detection of cam morphology and acetabular dysplasia.

References:

1. Stotter C, Klestil T, Roder C, Reuter P, Chen K, Emprechtinger R, et al. Deep Learning for Fully Automated Radiographic Measurements of the Pelvis and Hip. *Diagnostics (Basel)*. 2023;13(3).
2. Archer H, Reine S, Alshaikhsalama A, Wells J, Kohli A, Vazquez L, et al. Artificial intelligence-generated hip radiological measurements are fast and adequate for reliable assessment of hip dysplasia: an external validation study. *Bone Jt Open*. 2022;3(11):877-84.
3. Schwarz GM, Simon S, Mitterer JA, Huber S, Frank BJ, Aichmair A, et al. Can an artificial intelligence powered software reliably assess pelvic radiographs? *Int Orthop*. 2023;47(4):945-53.
4. Frysz M, Faber BG, Ebsim R, Saunders FR, Lindner C, Gregory JS, et al. Machine Learning-Derived Acetabular Dysplasia and Cam Morphology Are Features of Severe Hip Osteoarthritis: Findings From UK Biobank. *J Bone Miner Res*. 2022;37(9):1720-32.

QUESTION 3

How are imaging examinations of the hip joint and groin region used to identify pathology?

Statement:

Labral and cartilaginous pathology at the hip

Imaging can identify chondrolabral pathology. It is important to consider the high prevalence of labral and cartilage abnormalities on imaging in asymptomatic populations. Imaging findings must be considered alongside the clinical picture when interpreting them. Imaging alone should not be used as the main guide for treatment.

Radiographs

If radiographs show osteoarthritis then labral and/or cartilage pathology are present. The absence of radiographic signs of osteoarthritis does not exclude labral and/or cartilage pathology.

Advanced imaging

If the clinical picture warrants further investigation then MRI, MRA and CTA can evaluate labral and /or cartilage pathologies. MRI is preferred over CT.

A 1.5T MRA is currently the most widespread technique to detect labral and chondral pathologies. 3T MRI has similar reliability while 3T MRA is even more accurate. The use of IV contrast is not recommended. 1.5T MRA can detect many cartilage abnormalities but 3T MRI is more sensitive. Local availability and resources play a role in which advanced imaging should be requested. MRA also offers the opportunity for diagnostic local anaesthetic injection in addition to the imaging itself. Radial reformations from MRI and CT are more accurate in assessing the femoral head-neck junction. Several MRI-based classifications for describing labral lesions have been proposed; however, there is lack of agreement as to which classification is optimal. The consensus group does not suggest one classification over the other and recommends MRI reporting of labral injuries should be descriptive.

Adductor and pubic related groin pain (including pubic apophysitis)

Bone marrow oedema (BME) on MRI is often present in asymptomatic athletes. A higher grade of BME seems to be associated with the presence of groin pain in athletes. Imaging changes of the adductor tendons on ultrasound and MRI are common in asymptomatic athletes. There is conflicting evidence about the secondary cleft sign, though it may be associated with the presence of groin pain and a longer recovery time. Protrusion of the symphyseal disc may be associated with the presence of groin pain, and is often not reported in studies.

A lack of information on the normal imaging findings pertaining to pubic apophyseal maturation makes clinical interpretation challenging. Radiographs can assess the maturity of the pubic symphysis. MRI with ZTE sequences can potentially assess the maturity of the pubic symphysis if a diagnosis of pubic apophysitis is considered.

Inguinal-related groin pain

There is a high prevalence of bulging in asymptomatic athletes on dynamic ultrasonographic assessment, and as such there is a high risk of false-positive findings. Imaging findings always need to be interpreted along with the clinical picture. Ultrasound can also be used if there is suspicion of an inguinal hernia.

Iliopsoas-related groin pain

There is little known about the role of imaging in iliopsoas-related groin pain. Imaging can often be normal in the presence of the clinical entity. Dynamic ultrasound can sometimes be helpful to visualise snapping of the iliopsoas tendon if there is clinical doubt.

Section summary groin pain

It is important to note that imaging findings of the pubic symphysis and soft tissue structures – adductor tendons and insertions, bulging of the inguinal canal are highly prevalent in asymptomatic athletic individuals. There may be an association with higher degrees of pubic bone marrow oedema, symphyseal disc protrusion and secondary cleft sign with the presence of groin pain.

The weak associations, high prevalence of findings in healthy individuals emphasise that imaging as always needs to be interpreted based on the clinical findings.

Grade of recommendation: C

Agreement: median 9 (7-9)

Literature summary:

Labrum and cartilage abnormalities

Radiographs can indirectly help assess chondral abnormalities by depicting hip joint space narrowing and secondary osteoarthritic changes such as subchondral sclerosis, cysts and osteophytes (Mascarenhas 2020). In the absence of osteoarthritis findings on radiography in a young adult athlete, imaging techniques such as MRI, direct MR-arthrography (MRA) and CT-arthrography (CTA) are helpful in decision making as they may demonstrate focal or regional cartilage lesions despite a lack of or minimal radiographic findings of osteoarthritis (Mascarenhas 2020). (Unless otherwise noted, all references to MRA in this review denote MR-arthrography with intra-articular contrast injection.) The role of US in femoroacetabular impingement (FAI) is currently limited to the guidance of hip injections (Castro 2020).

Mascarenhas VV, Castro MO, Rego PA, et al. The Lisbon Agreement on Femoroacetabular Impingement Imaging-part 1: overview. *Eur Radiol.* 2020 Oct;30(10):5281-5297. **Level 2, consensus statement.**

Castro MO, Mascarenhas VV, Afonso PD, Rego P, Schmaranzer F, Sutter R, Kassarian A, Sconfienza L, Dienst M, Ayeni OR, Beaulé PE, Dantas P, Lalam R, Weber MA, Vanhoenacker FM, Dietrich TJ, Jans L, Robinson P, Karantanas AH, Sudół-Szopińska I, Anderson S, Noebauer-Huhmann I, Marin-Peña O, Collado D, Tey-Pons M, Schmaranzer E, Padron M, Kramer J, Zingg PO, De Maeseneer M, Llopis E. The Lisbon Agreement on Femoroacetabular Impingement Imaging-part 3: imaging techniques. *Eur Radiol.* 2021 Jul;31(7):4652-4668. doi: 10.1007/s00330-020-07501-5. **Level 2, consensus statement.**

Magnetic resonance imaging (MRI)

Despite rapid advances in musculoskeletal imaging, the workhorse still remains 1.5T MRI worldwide. An MRI field strength of 1.5 T should be the minimum used in FAI assessment (Saied 2017, Smith 2012). For imaging of labral abnormalities, the literature supports the use of 1.5T MRA with good accuracy and reproducibility (Robinson 2012). However, 1.5T MRI and MRA assessments of articular cartilage have been evaluated in fewer studies. These found a lower accuracy compared with labral assessment (during surgery??) and poorer interobserver agreement (Robinson 2012).

Unenhanced MRI and MRA are the techniques of choice for the detection of hip labrum and cartilage, although evidence indicates MRA as the best technique to study intra-articular pathology (Saied 2017, Smith 2012, Sutter 2014).

In a meta-analysis of studies with surgery as the reference standard, the pooled sensitivity and specificity for detection of labral lesions on MRI were 0.87 and 0.83, respectively, and on MRA were 0.91 and 0.58, respectively (Saied 2017). For chondral lesions, the pooled sensitivity and specificity MRI were 0.76 and 0.72, and for MRA were 0.75 and 0.79 (Saied 2017).

3T MRI is reported to be equivalent to 1.5T MRA for diagnosing labral tears and cartilage delamination, but superior for acetabular cartilage defects. Additionally, 3-T MRI demonstrated similar sensitivity to 3T MRA in the detection of acetabular labral tears, although the latter is more sensitive for the detection of acetabular chondral lesions (Chopra 2019, Saied 2017, Smith 2012, Crespo-Rodríguez AM 2017, Smith TO 2010).

This means that with the increasing availability of 3T MRI we now have the ability to provide routine and less invasive assessment of the hip labrum when compared to MRA (Robinson 2012, Zhang 2022).

When comparing 3T MRI and MRA, there are conflicting reports. In a series of 43 consecutive patients who underwent MR and MRA examinations and later arthroscopy, 3T MR demonstrated sensitivity for detection of acetabular labral tears that rivals the sensitivity of 3T MRA of the hip (Magee 2015). In this series, 3T MRA was more sensitive than conventional 3T MRI for detection of acetabular chondral defects (Magee 2015). On the other hand, Tian et al. (2014) suggested that conventional hip MR at 3T is not effective enough for evaluating the acetabular labral tears, with a relatively low sensitivity (61%-66% vs. 91%-93%) and specificity (74%-77% vs. 85%) in 90 patients, compared to surgery. They concluded that even at 3T, hip MRA is recommended for diagnosing acetabular labral lesions (Tian 2014).

The clinical question is whether the invasive nature of MRA, along with the ionizing radiation that imaging-guided injection usually entails and the risk of the actual injection, is justified or will change our clinical decision for treatment over a 3T MRI.

Indirect MRA (MRA with intravenous, instead of intra-articular, injection) is generally not indicated (Mascarenhas 2020).

There are no data regarding the use of hip traction during non-arthrographic MRI and little data regarding traction with indirect MRA for evaluating labral tears and cartilage lesions (Schmaranzer 2015, Llopis E 2008, Mascarenhas 2020). MRA with and without traction of the hip was shown to be highly accurate in identifying central and peripheral intra-articular bodies (Schmaranzer 2019).

References:

1. Saied AM, Redant C, El-Batouty M et al (2017) Accuracy of magnetic resonance studies in the detection of chondral and labral lesions in femoroacetabular impingement: systematic review and meta-analysis. *BMC Musculoskelet Disord* 18(1):83
2. Smith TO, Simpson M, Ejindu V, Hing CB (2012) The diagnostic test accuracy of magnetic resonance imaging, magnetic resonance arthrography and computer tomography in the detection of chondral lesions of the hip. *Eur J Orthop Surg Traumatol* 23(3):335–344
3. Robinson P. Conventional 3-T MRI and 1.5-T MR arthrography of femoroacetabular impingement. *AJR Am J Roentgenol.* 2012 Sep;199(3):509-15.
4. Sutter R, Zubler V, Hoffmann A et al (2014) Hip MRI: how useful is intraarticular contrast material for evaluating surgically proven lesions of the labrum and articular cartilage? *AJR Am J Roentgenol* 202(1):160–169

5. Chopra A, Grainger AJ, Dube B, Evans R, Hodgson R, Conroy J, Macdonald D, Robinson P. Comparative reliability and diagnostic performance of conventional 3T magnetic resonance imaging and 1.5T magnetic resonance arthrography for the evaluation of internal derangement of the hip. *Eur Radiol*. 2018 Mar;28(3):963-971. doi: 10.1007/s00330-017-5069-4.
6. Crespo-Rodríguez AM, De Lucas-Villarrubia JC, PastranaLedesma M, Hualde-Juvera A, Méndez-Alonso S, Padron M (2017) The diagnostic performance of non-contrast 3-Tesla magnetic resonance imaging (3-T MRI) versus 1.5-Tesla magnetic resonance arthrography (1.5-T MRA) in femoro-acetabular impingement. *Eur J Radiol* 88:109–116
7. Smith TO, Hilton G, Toms AP, Donell ST, Hing CB (2010) The diagnostic accuracy of acetabular labral tears using magnetic resonance imaging and magnetic resonance arthrography: a meta-analysis. *Eur Radiol* 21(4):8
8. Zhang P, Li C, Wang W, Zhang B, Miao W, Liu Y. 3.0 T MRI is more recommended to detect acetabular labral tears than MR Arthrography: an updated meta-analysis of diagnostic accuracy. *J Orthop Surg Res*. 2022 Mar 1;17(1):126.
9. Magee T. Comparison of 3.0-T MR vs 3.0-T MR arthrography of the hip for detection of acetabular labral tears and chondral defects in the same patient population. *Br J Radiol*. 2015 Sep;88(1053):20140817
10. Tian CY, Wang JQ, Zheng ZZ, Ren AH. 3.0 T conventional hip MR and hip MR arthrography for the acetabular labral tears confirmed by arthroscopy. *Eur J Radiol*. 2014 Oct;83(10):1822-7.
11. Mascarenhas VV, Castro MO, Rego PA, et al. The Lisbon Agreement on Femoroacetabular Impingement Imaging-part 1: overview. *Eur Radiol*. 2020 Oct;30(10):5281-5297.
12. Schmaranzer F, Klauser A, Kogler M et al (2015) Diagnostic performance of direct traction MR arthrography of the hip: detection of chondral and labral lesions with arthroscopic comparison. *Eur Radiol* 25(6):1721–1730
13. Llopis E, Cerezal L, Kassarian A, Higuera V, Fernandez E (2008) Direct MR arthrography of the hip with leg traction: feasibility for assessing articular cartilage. *AJR Am J Roentgenol* 190(4):1124–1128
14. Schmaranzer F, Lerch TD, Strasser U, Vavron P, Schmaranzer E, Tannast M. Usefulness of MR Arthrography of the Hip with and without leg Traction in Detection of Intra-articular Bodies. *Acad Radiol*. 2019 Sep;26(9):e252-e259. doi: 10.1016/j.acra.2018.10.008.

MRI-based labrum lesion classification

Several surgical and MRI-based classifications for the description of labrum lesions have been proposed (Beck 2005, Czerny 1996, Seldes 2001).

In MRI studies to date, along with surgical series, there has been no clear acceptance of a single classification for labral abnormalities or of a reproducible nomenclature for describing the positioning of acetabular abnormalities. Due to the heterogeneous classifications, imaging assessment of the acetabular labrum should focus on an accurate descriptive report, including location, configuration and extent of labral tears and associated cartilage and osseous changes (Schmaranzer 2017). Tear classification has also varied from the complicated (multiple positions with subsections for degenerative cystic findings and so on) to the relatively simple (e.g., normal, basal, or radial intra-substance) (Robinson 2012).

Such description can conceptually be applied to any MRI examination and is the recommendation of the Lisbon Agreement on FAI Imaging (Mascarenhas 2020).

A shape or >25% size difference of 15% and 25%, respectively, between labra on bilateral hips were identified on MRI in asymptomatic volunteers (Aydingöz 2001).

References:

1. Beck M, Kalhor M, Leunig M, Ganz R (2005) Hip morphology influences the pattern of damage to the acetabular cartilage. *J Bone Joint Surg Br* 87:1012–1018.
2. Czerny C, Hofmann S, Neuhold A et al (1996) Lesions of the acetabular labrum: accuracy of MR imaging and MR arthrography in detection and staging. *Radiology* 200:225–230.
3. Seldes RM, Tan V, Hunt J, Katz M, Winiarsky R, Fitzgerald RH Jr (2001) Anatomy, histologic features, and vascularity of the adult acetabular labrum. *Clin Orthop Relat Res*:232–240
4. Schmaranzer F, Todorski IAS, Lerch TD, Schwab J, CullmannBastian J, Tannast M (2017) Intra-articular lesions: imaging and surgical correlation. *Semin Musculoskelet Radiol* 21:487–506.
5. Robinson P. Conventional 3-T MRI and 1.5-T MR arthrography of femoroacetabular impingement. *AJR Am J Roentgenol.* 2012 Sep;199(3):509-15.
6. Mascarenhas VV, Castro MO, Rego PA, et al. The Lisbon Agreement on Femoroacetabular Impingement Imaging-part 1: overview. *Eur Radiol.* 2020 Oct;30(10):5281-5297.
7. Aydingöz U, Oztürk MH. MR imaging of the acetabular labrum: a comparative study of both hips in 180 asymptomatic volunteers. *Eur Radiol.* 2001;11(4):567-74. doi: 10.1007/s003300000597.

MRI-based cartilage lesion identification

Although contrast material seepage into or abnormal linear signal identified within or displacing the acetabular cartilage appears to be very specific for cartilage abnormalities, neither finding is sensitive presumably because the delaminated cartilage can still be attached to the underlying bone and prevent contrast material entering the space underneath (Robinson 2012).

Although 1.5T MRA may show delamination of articular cartilage well, 3T MRI is probably better for detecting early cartilage abnormalities related to changes in cartilage composition (Robinson 2012).

Robinson P. Conventional 3-T MRI and 1.5-T MR arthrography of femoroacetabular impingement. *AJR Am J Roentgenol.* 2012 Sep;199(3):509-15.

Clinical relevance of MRI-detected labral tears and cartilage lesions

The prevalence of abnormal MRI findings in an asymptomatic population has been reported on numerous times for many years.

There are a few studies that show a high prevalence of MRI documented intra-articular hip pathology and, more specifically, labral tears, in asymptomatic volunteers and patients.

One study (Tresch 2017) found a prevalence of labrum and cartilage abnormalities of 57% in asymptomatic volunteers versus 80% in symptomatic patients. Several studies report on intrasubstance labral degeneration, labrocartilaginous separation, and intrasubstance tears in up to 69% of asymptomatic individuals. Another study reported a >80% prevalence of MRI-documented labral tears in asymptomatic volunteers (Schmitz 2012). Regarding an athletic population, one study reported a 64% prevalence of MRI intra-articular hip pathology in asymptomatic collegiate and professional hockey players (Silvis 2011). Blankenstein et al. (2020) looked at asymptomatic professional rugby and ballet dancers and reported 87% MRI

prevalence of labral tears. Finally, a systematic review and meta-analysis by Heerey et al. (2018) evaluated the prevalence of MRI defined intra-articular hip abnormalities in people with and without pain. The prevalence of MRI documented labral tears in 29 studies was 62% in symptomatic and 54% in asymptomatic individuals.

Based on the many false-positive findings and the lack of understanding between the specific underlying pathology and its specific manifestation on imaging, utilizing imaging as the main guide for treatment is not recommended. Labral tears should only be considered relevant with an adequate patient history and suggestive clinical examination (Thorborg 2018, Griffin 2016).

References:

1. Tresch F, Dietrich TJ, Pfirrmann CWA, Sutter R. Hip MRI: Prevalence of articular cartilage defects and labral tears in asymptomatic volunteers. A comparison with a matched population of patients with femoroacetabular impingement. *J Magn Reson Imaging*. 2017 Aug;46(2):440-451.
2. Schmitz MR, Campbell SE, Fajardo RS, Kadrmaz WR. Identification of acetabular labral pathological changes in asymptomatic volunteers using optimized, noncontrast 1.5-T magnetic resonance imaging. *Am J Sports Med*. 2012 Jun;40(6):1337-41.
3. Silvis ML, Mosher TJ, Smetana BS, Chinchilli VM, Flemming DJ, Walker EA, Black KP. High prevalence of pelvic and hip magnetic resonance imaging findings in asymptomatic collegiate and professional hockey players. *Am J Sports Med*. 2011 Apr;39(4):715-21.
4. Blankenstein T, Grainger A, Dube B, Evans R, Robinson P. MRI hip findings in asymptomatic professional rugby players, ballet dancers, and age-matched controls. *Clin Radiol*. 2020 Feb;75(2):116-122.
5. Heerey JJ, Kemp JL, Mosler AB, Jones DM, Pizzari T, Souza RB, Crossley KM. What is the prevalence of imaging-defined intra-articular hip pathologies in people with and without pain? A systematic review and meta-analysis. *Br J Sports Med*. 2018 May;52(9):581-593
6. Thorborg K, Reiman MP, Weir A, Kemp JL, Serner A, Mosler AB, Hölmich P. Clinical Examination, Diagnostic Imaging, and Testing of Athletes With Groin Pain: An Evidence-Based Approach to Effective Management. *J Orthop Sports Phys Ther*. 2018 Apr;48(4):239-249.
7. Griffin DR, Dickenson EJ, O'Donnell J, et al. The Warwick Agreement on femoroacetabular impingement syndrome (FAI syndrome): an international consensus statement. *Br J Sports Med*. 2016; 50: 1169– 117

Do we need advanced imaging or are clinical examination and radiographs sufficient to make a clinical decision?

A study by Cunningham et al. (2017) examined cost-effective diagnostic strategies for symptomatic FAI, comparing history and physical examination alone (utilizing only radiographic imaging) with supplementation of an injection, MRI, or MRA. The authors concluded that providers should not routinely rely on advanced imaging to diagnose FAI syndrome, although advanced imaging may have a role in challenging clinical scenarios.

In an equally provocative paper, Ramkumar et al. (2022) suggested that once indicated for surgery based on history, physical examination, and radiographs, preoperative MRI did not alter the surgical plan for patients aged ≤ 40 years with FAIS undergoing primary hip arthroscopy. Moreover, preoperative MRI delayed time to arthroscopy. The necessity of routine preoperative MRI in the young primary FAI population should be challenged.

References:

1. Cunningham DJ, Paranjape CS, Harris JD, Nho SJ, Olson SA, Mather RC 3rd. Advanced Imaging Adds Little Value in the Diagnosis of Femoroacetabular Impingement Syndrome. *J Bone Joint Surg Am.* 2017 Dec 20;99(24):e133.
2. Ramkumar PN, Helm JM, Berrier AS, Vega JF, Yalcin S, Kunze KN, Harris JD, Nwachukwu BU. Preoperative Magnetic Resonance Imaging Offers Questionable Clinical Utility, Delays Time to Hip Arthroscopy, and Lacks Cost-Effectiveness in Patients Aged ≤ 40 Years With Femoroacetabular Impingement Syndrome: A Retrospective 5-Year Analysis. *Arthroscopy.* 2022 Nov;38(11):3013-3019.

Computed tomography (CT)

Although volumetric CT is excellent at depicting osseous morphology and assessing osteoarthritic changes, and may be used in virtual range of motion 3D simulation studies (Samim 2019), it is associated with significant ionizing radiation exposure in this frequently young population.

Ha et al. (2013) looked at 58 hips where 41 were diagnosed to have labral tears on CTA. Forty-three of the 58 hips were shown to have a labral tear on arthroscopy. Sensitivity, specificity, and accuracy for detecting labral tear and sulcus by CTA were good, being above 90%, for both observers. The authors concluded that CTA may be a useful diagnostic technique in the detection of acetabular labral tear.

Christie-Large et al. (2010) looked at 96 patients who had undergone CTA to evaluate its role in the diagnosis of intra-articular hip pathology. They report a discrepancy between the findings of a labral tear in one patient (false negative, 90% sensitivity and 100% specificity) concluding that CTA affords accurate detection of intra-articular hip pathology.

Yoo et al. (2017) looked into utilizing CTA morphologic changes in smaller sized labra after acetabular labral repair comparing preoperative and postoperative CTA. They concluded that repaired labra are well visualized post operatively with CTA.

In a comparative study between MRI and CTA in diagnosing labral tears and cartilage lesions, Lee et al. (2019) reported the sensitivity, specificity, and accuracy of MRI for detection of acetabular labral tears by two observers as 60%, 80%, and 64%, respectively, and 65%, 70%, and 69%, respectively. The sensitivity, specificity, and accuracy of CTA for detection of labral tears by both observers were 85%, 90%, and 86%, respectively, and 92%, 80%, and 89%, respectively. The study demonstrated that CTA was reliable in the diagnosis of acetabular labral tears. However, CTA (like MRI) was of limited value to detect cartilage lesions (Lee 2019).

References:

1. Samim M, Eftekhary N, Vigdorichik JM, Elbuluk A, Davidovitch R, Youm T et al (2019) 3D-MRI versus 3D-CT in the evaluation of osseous anatomy in femoroacetabular impingement using Dixon 3D FLASH sequence. *Skeletal Radiol* 48(3):429–436

2. Ha YC, Choi JA, Lee YK, Kim JY, Koo KH, Lee GY, Kang HS. The diagnostic value of direct CT arthrography using MDCT in the evaluation of acetabular labral tear: with arthroscopic correlation. *Skeletal Radiol.* 2013 May;42(5):681-8.
3. Christie-Large M, Tapp MJ, Theivendran K, James SL. The role of multidetector CT arthrography in the investigation of suspected intra-articular hip pathology. *Br J Radiol.* 2010 Oct;83(994):861-7.
4. Yoo JI, Ha YC, Lee YK, Lee GY, Yoo MJ, Koo KH. Morphologic Changes and Outcomes After Arthroscopic Acetabular Labral Repair Evaluated Using Postoperative Computed Tomography Arthrography. *Arthroscopy.* 2017 Feb;33(2):337-345.
5. Lee GY, Kim S, Baek SH, Jang EC, Ha YC. Accuracy of Magnetic Resonance Imaging and Computed Tomography Arthrography in Diagnosing Acetabular Labral Tears and Chondral Lesions. *Clin Orthop Surg.* 2019 Mar;11(1):21-27.

Ultrasonography (US)

The role of US in diagnosis of labral pathology is limited given incomplete evaluation of the entire labrum (Jacobson 2012).

Several recent studies showed a high sensitivity for US in the diagnosis of labral tears.

Gao et al. enrolled 195 patients in their study. Of these, 184 had arthroscopically confirmed anterosuperior acetabular labral tear. The sensitivity, specificity, positive predictive value (PPV), negative predictive value, and accuracy by US were 69%, 82%, 99%, 13%, and 69%, respectively. For MRI, the sensitivity, specificity, PPV, negative predictive value, and accuracy were 85%, 64%, 98%, 20%, and 84%, respectively. Although US had a slightly lower sensitivity for detecting anterosuperior acetabular labral tears, it had a higher specificity and PPV than MRI. With the advantages of being inexpensive, relatively quick, non-invasive, and possibility of dynamic evaluation, US could be used as a feasible method to evaluate anterosuperior acetabular labral tears.

Orellana et al. evaluated 44 patients with FAIS, whereby US changes were found in 93%, with 64% showing some kind of labral abnormality and 41% showing articular cartilage abnormalities. The authors concluded that US showed abnormalities in a significant proportion of patients with symptomatic FAIS in early phases of the disease. Additional longitudinal studies are warranted to establish the prognostic importance of these US changes.

No consensus was reached for the use of US in hip labrum and cartilage abnormalities by an expert panel, which concluded that the role of US is currently limited to the guidance of hip injections (Castro 2020).

References:

1. Jacobson JA, Bedi A, Sekiya JK, Blankenbaker DG. Evaluation of the painful athletic hip: imaging options and imaging-guided injections. *AJR Am J Roentgenol.* 2012 Sep;199(3):516-24.
2. Gao G, Fu Q, Cui L, Xu Y. The Diagnostic Value of Ultrasound in Anterosuperior Acetabular Labral Tear. *Arthroscopy.* 2019 Sep;35(9):2591-2597.

3. Orellana C, Moreno M, Calvet J, Navarro N, García-Manrique M, Gratacós J. Ultrasound Findings in Patients With Femoroacetabular Impingement Without Radiographic Osteoarthritis: A Pilot Study. *J Ultrasound Med.* 2019 Apr;38(4):895-901
4. Castro MO, Mascarenhas VV, Afonso PD, Rego P, Schmaranzer F, Sutter R, Kassarian A, Sconfienza L, Dienst M, Ayeni OR, Beaulé PE, Dantas P, Lalam R, Weber MA, Vanhoenacker FM, Dietrich TJ, Jans L, Robinson P, Karantanas AH, Sudol-Szopińska I, Anderson S, Noebauer-Huhmann I, Marin-Peña O, Collado D, Tey-Pons M, Schmaranzer E, Padron M, Kramer J, Zingg PO, De Maeseneer M, Llopis E. The Lisbon Agreement on Femoroacetabular Impingement Imaging-part 3: imaging techniques. *Eur Radiol.* 2021 Jul;31(7):4652-4668. doi: 10.1007/s00330-020-07501-5.

Adductor and pubic related groin pain

In many imaging studies, no clear distinction is possible between adductor or pubic related groin pain. For these reasons the two are considered together in this section.

Bone marrow oedema

Bone marrow oedema (BME) on STIR MR sequences in the pubic bones can be assessed reliably. Some authors report that this is associated with a poor clinical long-term outcome in professional football players and should be regarded as a negative prognostic factor [Gaudino 2017]. Another study showed that in females the presence of BME on MRI prior to TEP abdominal wall surgery was associated with slightly longer recovery time. Another case series found the presence of BME prior to TEP surgery not to be associated with worse long term outcomes. Oedema in periarticular soft tissues, with extension to the muscles and tendons located around the symphyseal joint may or may not be related to pubic pain. MRI showed minimal or moderate BME at the pubic symphysis in half of the ice-hockey and football players without groin/hip symptoms [Paajanen 2011]. Only higher grades of pubic BME and a protrusion of the symphyseal joint disc were associated with pain in a case control study comparing inactive controls to asymptomatic football players to football players with adductor/pubic related groin pain [Branci].

Secondary cleft and adductor tendons

The reliability of examining the presence of adductor tendinopathy on pelvic MRI was found to be poor in an inter examiner study. Ultrasound has also been found to have good interobserver reliability to assess for changes in the proximal adductor tendon.

A high proportion of asymptomatic athletes have been found to have changes in the adductor tendon on MRI (>70%). All the healthy athletes examined with ultrasound had imaging changes in the proximal adductor tendon.

It should also be noted that there is confusion surrounding the nomenclature of changes of the proximal adductor tendons at the insertion. Terms like adductor enthesopathy, secondary cleft, pubic aponeurosis defect and adductor tendinopathy are used interchangeably.

The secondary cleft sign in MRI has been reported to be a marker of groin injury in athletes presenting with groin pain [Brennan 2005]. Other studies found no association between the presence of secondary cleft and having groin pain. Others have found that having a superior cleft was associated with better outcomes following a guided injection. Cleft sign (superior, inferior or secondary?) on MRI was found to be associated with a delayed return-to-play time in athletes with groin pain.

Pyramidalis–anterior pubic ligament–adductor longus complex (PLAC)

Schilders et al. recently introduced an anatomical concept of the pyramidalis–anterior pubic ligament–adductor longus complex (PLAC) in groin pain [2021]. An MRI classification of acute injuries has been published. These injuries can present at a later stage with long standing groin pain. The exact role of imaging in the chronic situation is unclear.

Symphyseal disc protrusion

In young and active individuals with adductor and/or pubic related groin pain a number of findings on MRI were associated with the presence of groin pain: high grades of bone marrow oedema and protrusion of the symphyseal disc. [Branci].

Conventional radiography

It has long been known that asymptomatic athletes often have radiographic changes of the pubic symphysis. An older classification was recently updated and found to be reliable in scoring changes at the pubic symphysis in male athletes. The association between imaging findings and the presence of groin pain or the prognosis is unknown.

Apophysitis

Normal perisymphysial pubic ossification is a prolonged process that extends into adulthood. The pubic bone around the symphysis ossifies with the development of dorsal and ventral ramparts, with billowing and separate ossicles on the surface of the joint (Katz and Suchey 1986, Fleischman 2013). A lack of knowledge and understanding of this can result in misinterpretation of normal ossification as injuries on imaging. A recently proposed classification (MAPS classification, van Ovost et al 2023) offers a reliable descriptive classification of the radiographic maturation of the pubic symphysis joint in athletic males. In adolescents or young adults pubic- or adductor-related groin pain could be due to apophysitis [Sailly 2015, Koh 2020].

The CT scans of young patients with groin pain demonstrated open pubic apophyses with stress-related physal changes (widening, asymmetry and small rounded cyst-like expansions) that were not observed in the comparison group. No comparison subject demonstrated apophyseal maturity before 21 years of age, and immaturity was seen up to the age of 26 years [Sailly 2015]. Traditionally CT scan was used for advanced imaging of the ossification and maturation of the pubic symphysis. It seems likely that MRI with ZTE sequences, that generate CT-like images, will replace CT for assessing bony changes of the pubic symphysis in young athletes (Aydingöz 2022). Apophysitis associated with adductor brevis-gracilis was more common than adductor longus-associated apophysitis in a study with ZTE MRI [Koh 2020].

Age-related changes on imaging (CT, MRI or MRI with ZTE) during normal maturation of the pubic apophysis needs further study in a large healthy, active and asymptomatic population.

Sailly M, Whiteley R, Read JW, Giuffre B, Johnson A, Hölmich P. Pubic apophysitis: a previously undescribed clinical entity of groin pain in athletes. *Br J Sports Med.* 2015 Jun;49(12):828-34. doi: 10.1136/bjsports-2014-094436.

Koh E, Boyle J. Pubic apophysitis in elite Australian Rules football players: MRI findings and the utility of VIBE sequences in evaluating athletes with groin pain. *Clin Radiol.* 2020 Apr;75(4):293-301. doi: 10.1016/j.crad.2019.12.022.

Katz D, Suchey JM. Age determination of the male os pubis. *Am J Phys Anthropol.* 1986 Apr;69(4):427-35. doi: 10.1002/ajpa.1330690402.

Fleischman JM. A comparative assessment of the Chen et al. and Suchey-Brooks pubic aging methods on a North American sample. *J Forensic Sci.* 2013;58(2):311-23.

Aydingöz Ü, Yıldız AE, Ergen FB. Zero Echo Time Musculoskeletal MRI: Technique, Optimization, Applications, and Pitfalls. *Radiographics.* 2022 Sep-Oct;42(5):1398-1414. doi: 10.1148/rg.220029. **Level 4, review.**

Ducouret E, Reboul G, Dalmy F, Losif C, Mounayer C, Pesquer L and Dallaudiere B. MRI in chronic groin pain: sequence diagnostic reliability compared to systematic surgical assessment. *Skeletal Radiol* 2018; 47:649–660. **Level 4, case series.**

Larson CM, Pierce BR and Giveans MR. Treatment of Athletes with Symptomatic Intra-Articular Hip Pathology and Athletic Pubalgia/Sports Hernia: A Case Series. *Arthroscopy* 2011; 27: 768-775. **Level 4, case series.**

Gaudino F, Spirab D, Bangert Y, Ottd H, Beomonte Zobela B, Kauczorb H-U, Weber M-A. Osteitis pubis in professional football players: MRI findings and correlation with clinical outcome. *Eur J Radiol* 2017;94: 46–52. **Level 4, case series.**

Paajanen H, Hermunen H, Karonen J. Effect of heavy training in contact sports on MRI findings in the pubic region of asymptomatic competitive athletes compared with non-athlete controls. *Skeletal Radiol* 2011; 40:89-94. **Level 3, prospective case series.**

Brennan D, O'Connell MJ, Ryan M, Cunningham P, Taylor D, Cronin C, O'Neill P, Eustace S Secondary cleft sign as a marker of injury in athletes with groin pain: MR image appearance and interpretation. *Radiology* 2005; 235:162-7. **Level 4, case series.**

Thorborg K, Reiman MP, Weir A, et al. Clinical Examination, Diagnostic Imaging, and Testing of Athletes With Groin Pain: An Evidence-Based Approach to Effective Management. *J Orthop Sports Phys Ther* 2018; 48: 239-249. **Level 4, review.**

Sailly M, Whiteley R, Read JW, Giuffre B, Johnson A, and Hölmich P. Pubic apophysitis: a previously undescribed clinical entity of groin pain in athletes. *Br J Sports Med* 2015; 49:828–834. **Level 4, case series.**

Koh E, Boyle J. Pubic apophysitis in elite Australian Rules football players: MRI findings and the utility of VIBE sequences in evaluating athletes with groin pain. *Clin Radiol* 2020; 75: 293-301. **Level 4, case series.**

Robinson P, Barron DA, Parsons W, Grainger AJ, Schilders EM, O'Connor PJ. Adductor-related groin pain in athletes: correlation of MR imaging with clinical findings. *Skeletal Radiol* 2004; 33:451-7. **Level 4, case series.**

Silvis ML, Mosher TJ, Smetana BS, Chinchilli VM, Flemming DJ, Walker EA, Black KP. High Prevalence of Pelvic and Hip Magnetic Resonance Imaging Findings in Asymptomatic Collegiate and Professional Hockey Players. *Am J Sports Med* 2011;39: 715-721. **Level 4, case series.**

Dallaudiere B, Sylvain B, Poussange N, Reboul G, Silvestre A, Meyer P, Hocquelet A, Pesquer L. Ultrasound feature variants of the adductor longus tendon in asymptomatic sportive subjects: Management implications. *Eur J Radiol* 2021; 144:109928. **Level 4, case series.**

Schilders E, Mitchell AWM, Johnson R, et al. Proximal adductor avulsions are rarely isolated but usually involve injury to the PLAC and pectineus: descriptive MRI findings in 145 athletes. *Knee Surg Sports Traumatol Arthrosc.* 2021; 29: 2424–2436. **Level 5, case series.**

Zoga AC, Kavanagh EC, Omar IM, Morrison WB, Koulouris G, Lopez H, Chaabra A, Domesek J, Meyers WC. Athletic pubalgia and the "sports hernia": MR imaging findings. *Radiology.* 2008; 247:797-807. **Level 4, case series.**

Bou Antoun M, Ronot M, Crombe A, Moreau-Durieux MH, Reboul G, Pesquer L. High insertion of conjoint tendon is associated with inguinal-related groin pain: a MRI study. *Eur Radiol.* 2020; 30:1517-1524. **Level 4, case series.**

Sheen AJ, Montgomery A, Simon T, Ilves I, Paajanen H. 2019. Randomized clinical trial of open suture repair versus totally extraperitoneal repair for treatment of sportsman's hernia. *BJS* 106:7, 837-844. **Level 1, RCT.**

Inguinal-related groin pain

Pain in the inguinal canal region with no actual hernia has been attributed to many different possible pathologies but the exact pathology remains unclear. Inguinal related groin pain is the preferred term.

Dynamic sonographic assessment can be accomplished using the Valsalva manoeuvre to look for bulging of the posterior wall of the inguinal canal. Sensitivity, specificity and negative predictive value of US in detecting clinically occult groin hernia (sports hernia) cannot reliably be determined based on current evidence [Kwee 2018]. Sixteen studies were included in one review and sensitivities varied between 29% and 91%, specificities between 90% and 91%. Accuracy may strongly depend on the examiners skills.

A high conjoint tendon insertion may be more frequent in athletes with groin pain and may be a predisposing factor. MRI could help predict the type of conjoint tendon insertion [Bou Antoun 2020]. In one randomized study, MRI was normal in 58% of athletes prior to operative treatment [Sheen 2019].

Inguinal and femoral true hernias can reliably be differentiated by US. However, bulging alone has not been associated with groin pain, and there is a high risk of false-positive findings due to the high prevalence of bulging in asymptomatic athletes [Thorborg 2018]. A study in young male academy football players found that 62% of asymptomatic athletes had bulging on ultrasound assessment.

Weir A, Brukner P, Delahunt E, et al. Doha agreement meeting on terminology and definitions in groin pain in athletes. *Br J Sports Med* 2015; 49:768–74. **Level 2, consensus statement.**

Kwee RM, Kwee TC. Ultrasonography in diagnosing clinically occult groin hernia: systematic review and meta-analysis. *Eur Radiol* 2018; 28:4550–4560. **Level 4, case series.**

Thorborg K, Reiman MP, Weir A, et al. Clinical Examination, Diagnostic Imaging, and Testing of Athletes With Groin Pain: An Evidence-Based Approach to Effective Management. *J Orthop Sports Phys Ther* 2018; 48: 239-249. **Level 4, review.**

Iliopsoas-related groin pain

Very few studies have been performed on iliopsoas-related groin pain and imaging findings. In a large cohort (n=638) of athletes with groin pain with both acute and gradual onset 134 were identified on MRI with iliopsoas related pathology. The MRI changes could be separated in 2 groups, one that showed signs of peritendinitis (66/638) and one that

showed signs of muscle strain (68/638). The group that showed signs of peritendinitis had significantly longer return to sport time.

Anterior snapping hip is common in asymptomatic individuals. A detailed study using dynamic ultrasound showed that the most common causes was a flipping of the iliopsoas tendon around the iliac muscle, but it can also be the result of the iliopsoas tendon moving suddenly across different bony prominences in the pelvis.

Tsukada S, Niga S, Nihei T, et al. Iliopsoas Disorder in Athletes with Groin Pain: Prevalence in 638 Consecutive Patients Assessed with MRI and Clinical Results in 134 Patients with Signal Intensity Changes in the Iliopsoas. *JB JS Open Access*. 2018;3(1):e0049.

Musick SR, Varacallo M. Snapping Hip Syndrome. [Updated 2023 Aug 4]. In: StatPearls [Internet]. Treasure Island (FL): StatPearls Publishing; 2023 Jan-. Available from: <https://www.ncbi.nlm.nih.gov/books/NBK448200/>
Deslandes M, Guillin R, Cardinal E, Hobden R, Bureau NJ. The snapping iliopsoas tendon: new mechanisms using dynamic sonography. *AJR Am J Roentgenol*. 2008 Mar;190(3):576-81. doi: 10.2214/AJR.07.2375. PMID: 18287424.

QUESTION 4

Are imaging examinations of the hip and groin able to give information about the prognosis?

Statement:

There are very few studies examining the role of imaging for the prognosis in hip and groin pain in active individuals. The exact role is unclear.

Grade of recommendation: C

Agreement: median 8 (2-9)

Literature summary:

We believe that this question should be clarified regarding the short-term (i.e., return to play) and long-term (i.e., development of osteoarthritis [OA]) prognoses.

There is currently no strong evidence to suggest an improvement of diagnostic or prognostic indicators with imaging [Branci 2013]. Some evidence exists that increasing alpha angle and larger cam deformity is associated with the development of hip-related symptoms and prognosis, whereas pincer type morphology was not [Larson 2018]. In prospective studies, the presence of acetabular dysplasia and the presence of cam morphology are associated with an increased risk of osteoarthritis development in middle-aged symptomatic cohorts presenting with hip pain [Thorborg 2018, Agricola 2013 (1), Agricola 2013 (2), Nicholls 2011].

Outcome of endoscopic surgery demonstrates that the presence of severe pubic BME may predict slightly prolonged recovery from surgery and return to sport particularly in females

[Matikainen 2017, Kuikka 2015]. Cleft sign on MRI was found to be associated with a delayed return-to-play time in athletes with groin pain.

Agricola R, Waarsing JH, Thomas GE, et al. Cam impingement: defining the presence of a cam deformity by the alpha angle: data from the CHECK cohort and Chingford cohort. *Osteoarthritis Cartilage*. 2014;22:218-225. <https://doi.org/10.1016/j.joca.2013.11.007>

Saberi Hosnijeh F, Zuiderwijk ME, Versteeg M, et al. Cam deformity and acetabular dysplasia as risk factors for hip osteoarthritis. *Arthritis Rheumatol*. 2017;69:86-93. <https://doi.org/10.1002/art.39929>

Branci S, Thorborg K, Nielsen MB, Hölmich P. Radiological findings in symphyseal and adductor-related groin pain in athletes: a critical review of the literature. *Br J Sports Med*. 2013; 47:611-619. **Level 4, review.**

Larson CM, Safran MR, Brcka DA, Vaughn ZD, Giveans MR, and Stone RM. Predictors of clinically suspected intra-articular hip symptoms and prevalence of hip pathomorphologies presenting to sports medicine and hip preservation orthopaedic surgeons. *Arthroscopy* 2018; 34: 825-831. **Level 4, case series.**

Thorborg K, Reiman MP, Weir A, Kemp JL, Serner A, Mosler AB, Hölmich P. Clinical Examination, Diagnostic Imaging, and Testing of Athletes With Groin Pain: An Evidence-Based Approach to Effective Management. *J Orthop & Sports Phys Ther* 2018; 48: 239-249. **Level 4, review.**

Agricola R, Heijboer MP, Bierma-Zeinstra SM, Verhaar JA, Weinans H, Waarsing JH. Cam impingement causes osteoarthritis of the hip: a nationwide prospective cohort study (CHECK). *Ann Rheum Dis*. 2013; 72:918-923. <https://doi.org/10.1136/annrheumdis-2012-201643>

Agricola R, Heijboer MP, Roze RH, et al. Pincer deformity does not lead to osteoarthritis of the hip whereas acetabular dysplasia does: acetabular coverage and development of osteoarthritis in a nationwide prospective cohort study (CHECK). *Osteoarthritis Cartilage*. 2013; 21:1514-1521.

Nicholls AS, Kiran A, Pollard TC, et al. The association between hip morphology parameters and nineteen-year risk of end-stage osteoarthritis of the hip: a nested case-control study. *Arthritis Rheum*. 2011;63:3392-3400. <https://doi.org/10.1002/art.30523>

Griffin DR, Dickenson EJ, O'Donnell J, et al. The Warwick Agreement on femoroacetabular impingement syndrome (FAI syndrome): an international consensus statement. *Br J Sports Med* 2016; 50:1169–1176. **Level 2, consensus statement.**

Reiman MP, Thorborg K. Femoroacetabular impingement surgery: are we moving too fast and too far beyond the evidence? *Br J Sports Med* 2015; 49:782–784. **Level 4, review.**

Matikainen M, Hermunen H, Paajanen H. Athletic pubalgia in females. Predictive value of MRI in outcomes of endoscopic surgery. *Orthop J Sports Med* 2017; 5(8): 1-5. **Level 4, case series.**

Kuikka L, Hermunen H, Paajanen H. Effect of pubic bone marrow oedema on recovery from endoscopic surgery for athletic pubalgia. *Scand J Med Sci Sports* 2015; 25:98-103. **Level 3, prospective case series.**

Pezzotta G, Pecorelli A, Querques G, Biancardi S, Morzenti C, Sironi S. MRI characteristics of adductor longus lesions in professional football players and prognostic factors for return to play. *Eur J Radiol* 2018; 108: 52–58. **Level 4, case series.**

QUESTION 5

Are diagnostic injections with local anaesthetic into the hip joint able to identify intraarticular pathology?

Statement:

Pain relief obtained from a local I/A hip injection can reliably differentiate intraarticular pathology from extra-articular pathology

The local anaesthetic intra-articular hip injection should be guided by US or fluoroscopy.

The clinician should bear in mind that the diagnosis of hip pathology is formulated based on a patient's history, physical examination, imaging, and other supporting tests, which include local anaesthetic intra-articular hip injection.

Grade of recommendation: C

Agreement : median 9 (5-9)

Literature summary:

We searched MEDLINE, PubMed, and Google Scholar for studies that utilized intra-articular hip injections for differentiating hip pain prior to hip arthroscopy.

The search strategy combined the following terms: femoral acetabular impingement (FAI), hip impingement, intra-articular pathology, hip differential diagnosis and intra-articular injection. No time limit was placed in the search. The searching included the references of eligible full-text articles. Browsing the “related articles” feature in PubMed were also used to identify additional eligible studies.

Studies meeting the following inclusion criteria were included in this text: (1) adult patients (2) hip arthroscopy and (3) articles published in English.

The source of hip/groin pain can be elusive despite skilled physical examination and MRI, MRA, CT evaluation. Many surgeons rely heavily on the response to intraarticular anaesthetic injection (I/A) for the selection of candidates for whom arthroscopy may be appropriate. Pain relief resulting from such an injection has been associated with the presence of intraarticular pathology.

The diagnostic injection should be performed under guidance – U/S or fluoroscopy. It is interesting that in most of the published data it is administered by a musculoskeletal – radiologist rather than an orthopaedic surgeon. (1, 2,4,8,9)

There is no consistency in the literature on the pharmaceutical agents used for the I/A injection. For the local aesthetic (LA) it was ropivacaine, bupivacaine, lidocaine or a combination coupled with a steroid if the investigative protocol chose to document the long-term therapeutic effect of the injection. In some studies (1,2,9) the I/A administration used LA and MR pharmaceutical contrast (gadolinium, gadodiamide) if an MR-arthrogram followed the injection.

Randelli et al. Compared the image quality of magnetic resonance arthrography (MRA) of the hip with intra-articular injection of high-viscosity hyaluronic acid (HA-MRA) versus Gd-based contrast agent (Gd-MRA) in patients with femoroacetabular impingement (FAI). They concluded that image quality was comparable. This confirmed the use of the I/A injection in one single procedure as an image quality not significantly different from that of Gd-MRA. This may open the possibility of combining MRA and the analgesic affect of viscosupplementation in one single procedure.

Documentation of Response (positive or negative)

There is variation on the documentation of pre and post-injection response to the injection regarding pain. Ladd et al documented pre and post-injection pain scores based on patients performing provocative manoeuvres in the fluoroscopy room to elicit their typical symptoms. Such manoeuvres included hip flexion, abduction, internal rotation, external rotation, extension, formal FABER (flexion in abduction and external rotation) testing, or a combination of these manoeuvres. In another studies, the response was not based on clinical examination but rather the patients were encouraged within 2 hours post-injection to perform activities or getting into positions that before aggravated their pain to determine his or her response to the local anaesthetic. (1,2,7,10)

To quantify the relief, the response was documented in a simple binary form: positive (temporary improvement in symptoms) or negative response if no improvement was noted

or if the improvement was only equivocal. (2) Using a form of a pain scale was more common with the use of the numerical rating scale (NRS), which measures pain intensity on a scale from 0 to 10 (8) or of the continuous scale from 0% relief (pain unchanged) to 100% relief (no pain) (7,10).

In one study where LA and steroid was used, patients were asked to keep a daily pain diary for 2 weeks to document their pain response categorically as either none, partial, or complete. Patients were encouraged to engage in provocative activities during the 2-week interval and to document any pain as a result of these activities on a daily basis (1). In a variation of the above Gao et al. recorded a “positive response” meaning more than 50% pain relief from the pre-injection pain level and “negative response” meaning less than that. Interestingly, Negative responders were interviewed about pain relief 1 week after injection. If they had responded positively to the steroid within 1 week, these patients (10/78) were also regarded as delayed “positive response.” This would suggest that clinicians should consider the use of a therapeutic agent (steroid or viscosupplementation) during I/A injections in order to account for delayed responders to the injection.

Reported outcome (Pain Relief)

As result of the variable ways of documenting the response to the pain relief provided by the I/A injection there are some noted variations on the response.

Byrd and Jones reported 92.5% (37/40) positive response immediately after LA injection. Ladd et al report good response in 41/93 (44%) moderate response 16/93 (17,2%) and poor response in 29/93 (31,2%) (good being 60% or more improvement, moderate 30-60% and poor less than 30%). Two studies noted immediate pain relief from injection on a scale from 0% (no relief) to 100% (complete relief), with Kivlan et al. observing a mean of 82.3% relief. In the paper by Martin et al. subjects were dichotomized into groups based on whether they reported greater than 50% pain relief (27/49) indication predominantly i/a source of symptoms or less than or equal to 50% pain relief (22/49) suggestion extra- articular involvement.

Krytch et al reported that all 54 patients (100%) experienced pain relief during the anaesthetic phase of the injection, confirming injection of anaesthetic and corticosteroid medication into the hip joint. Median pre-injection NRS score was 7.0 (range 2.5–10.0), median anaesthetic phase post-injection NRS score was 1.0 (range 0.0–5.0).

In a recent study by Gao et al., looked at 38 consecutive patients diagnosed with FAI and with atypical clinical symptoms who underwent US-guided hip injection before surgery. The response to the US-guided intra-articular injection was 91.7% accurate for detecting the presence of intra-articular abnormality verified during hip arthroscopy suggesting that I/A injection can supplement positively our clinical decision making even in the presence of non-typical symptoms and examination.

Response as prediction to outcome

Martin et al in their study tried to determine whether signs and symptoms could identify if most of the hip pain was originating from intra-articular sources in potential arthroscopic surgery candidates. They reported that a substantial proportion of patients (43%) with definite or possible labral tear on MR arthrogram did not experience >50% relief after injection, suggesting a possible extraarticular source of hip pain in many of these cases. They concluded that I/A not relieving all intra-articular pathologies shown on MRA suggests that all findings on MRA may not be contributors to the patient's complaints. Conversely, they only looked at labral tear and no other I/A hip pathology.

Kivlan et al. tried to correlate the I/A injection response to FAI, labral pathology, chondral pathology and extra-articular pathology and found that subjects with chondral damage had greater pain relief from the injection than those without, regardless of severity. The presence and severity of FAI and labral pathology did not influence the percent relief from injection.

A study by Ayeni et al. that evaluated preoperative intraarticular injection into the hip as a predictor of short-term outcome after arthroscopic management of FAI found no statistically significant positive correlation but, rather, a negative correlation in which lack of pain relief from anaesthetic injection may indicate poorer surgical outcomes after correction of FAI.

Krytch et al hypothesized that significant pain relief (>50%) after an IA diagnostic injection would correlate with better clinical outcomes after surgery but found that IA anaesthetic injections were poor predictors of outcome after hip arthroscopy; patients receiving more than 50% relief had similar outcomes to those who showed less than 50% relief. In this study, patients who had no relief from IA injection still benefitted from hip arthroscopy. In these patients, a positive clinical history (predominantly groin pain with prolonged sitting) and correlation of positive provocative impingement tests with location of anatomic impingement lesion on imaging were more important than a poor response to IA injection in determining whether they were a candidate for surgery.

Safety of diagnostic and therapeutic joint injections

Various, uncommon adverse events have been reported that may result from diagnostic and therapeutic musculoskeletal injections, including arthrography, being reported in 2.4% to 12% of patients. Most of these adverse events are very mild and self-limiting (12)

As a cautionary note, in a recent study Wang et al. suggested that the risk of infection after hip arthroscopy increased when preoperative intra-articular hip injections were given within 3 months of surgery. (14)

References:

1. Ayeni OR, Farrokhyar F, Crouch S, Chan K, Sprague S, Bhandari M. Pre-operative intra-articular hip injection as a predictor of short-term outcome following arthroscopic management of femoroacetabular impingement. *Knee Surg Sports Traumatol Arthrosc.* 2014 Apr;22(4):801-5. **Level IV, case series**

2. Byrd JW, Jones KS. Diagnostic accuracy of clinical assessment, magnetic resonance imaging, magnetic resonance arthrography, and intra-articular injection in hip arthroscopy patients. *Am J Sports Med.* 2004 Oct-Nov;32(7):1668-74. **Level IV, case series**
3. Gao G, Fu Q, Wu R, Liu R, Cui L, Xu Y. Ultrasound and Ultrasound-Guided Hip Injection Have High Accuracy in the Diagnosis of Femoroacetabular Impingement With Atypical Symptoms. *Arthroscopy.* 2021 Jan;37(1):128-135. **Level IV, case series**
4. Ladd LM, Keene JS, Del Rio AM, Rosas HG. Correlation Between Hip Arthroscopy Outcomes and Preoperative Anesthetic Hip Joint Injections, MR Arthrogram Imaging Findings, and Patient Demographic Characteristics. *AJR Am J Roentgenol.* 2016 Nov;207(5):1062-1069. **Level IV, case series**
5. Lynch TS, Steinhaus ME, Popkin CA, Ahmad CS, Rosneck J. Outcomes After Diagnostic Hip Injection. *Arthroscopy.* 2016 Aug;32(8):1702-11. **Level V systematic review**
6. Khan W, Khan M, Alradwan H, Williams R, Simunovic N, Ayeni OR. Utility of Intra-articular Hip Injections for Femoroacetabular Impingement: A Systematic Review. *Orthop J Sports Med.* 2015 Sep 1;3(9):2325967115601030. **Level V systematic review**
7. Kivlan BR, Martin RL, Sekiya JK. Response to diagnostic injection in patients with femoroacetabular impingement, labral tears, chondral lesions, and extra-articular pathology. *Arthroscopy.* 2011 May;27(5):619-27. **Level IV, therapeutic case series.**
8. Krych AJ, Sousa PL, King AH, Engasser WM, Levy BA. Intra-articular Diagnostic Injection Exhibits Poor Predictive Value for Outcome After Hip Arthroscopy. *Arthroscopy.* 2016 Aug;32(8):1592-600. **Level IV, therapeutic case series.**
9. Krych AJ, Griffith TB, Hudgens JL, Kuzma SA, Sierra RJ, Levy BA. Limited therapeutic benefits of intra-articular cortisone injection for patients with femoro-acetabular impingement and labral tear. *Knee Surg Sports Traumatol Arthrosc.* 2014 Apr;22(4):750-5. **Therapeutic case series, Level IV.**
10. Martin RL, Irrgang JJ, Sekiya JK. The diagnostic accuracy of a clinical examination in determining intra-articular hip pain for potential hip arthroscopy candidates. *Arthroscopy.* 2008 Sep;24(9):1013-8. **Level III, diagnostic study of nonconsecutive patients**
11. Mujahed T, Hassebrock JD, Makovicka JL, Pollock JR, Wilcox JG, Patel KA, Economopoulos KJ. Preoperative Intra-articular Steroid Injections as Predictors of Hip Arthroscopy: 2-Year Outcomes. *Orthop J Sports Med.* 2021 Nov 29;9(11):1-7. **Level IV, case series**
12. Peterson C, Hodler J. Adverse events from diagnostic and therapeutic joint injections: a literature review. *Skeletal Radiol.* 2011 Jan;40(1):5-12. **Level V systematic review**
13. Randelli F, Nocerino EA, Nicosia L, Ali M, Monti CB, Sardanelli F, Aliprandi A. Image quality of hip MR arthrography with intra-articular injection of hyaluronic acid versus gadolinium-based contrast agent in patients with femoroacetabular impingement. *Skeletal Radiol.* 2020 Jun;49(6):937-944 **Level IV, case series**
14. Wang D, Camp CL, Ranawat AS, Coleman SH, Kelly BT, Werner BC. The Timing of Hip Arthroscopy After Intra-articular Hip Injection Affects Postoperative Infection Risk. *Arthroscopy.* 2017 Nov;33(11):1988-1994.e1. **Level III, retrospective comparative study.**

CONCLUSIVE QUESTIONS

Question 1

When is imaging indicated for physically active adults with hip and groin pain?

Findings on imaging do not necessarily correlate with hip and groin symptoms in physically active adults. Imaging should only be performed in symptomatic patients following a systematic clinical assessment. It should also be noted that symptomatic patients may have normal imaging findings, and that many asymptomatic individuals have findings on imaging.

Current evidence does not support routine imaging screening for asymptomatic individuals.

Imaging provides morphometric analyses of the hip and pubic symphyseal joint and depicts the surrounding soft tissues. This can provide additional information on the suspected clinical condition and assist in planning optimal treatment.

Imaging should be considered when:

- There is clinical suspicion of underlying serious pathology.
- A patient with hip joint-related pain has not improved after a short course of non-surgical treatment.
- A patient with groin pain who does not respond to non-surgical treatment presents uncertainty of the clinical diagnosis.

Grade of Recommendation: C

Agreement: median 9 (7-9)

Question 2

In physically active adults with hip and groin pain, which imaging examinations are recommended as first line examinations? As second line examinations?

Costs in terms of resource allocation (money, workforce, time) and the burden of ionizing radiation must always be taken into consideration prior to requesting investigations.

An adequate anteroposterior pelvic radiograph along with a Dunn view or similar lateral view is the first-line imaging examination for the morphological evaluation of the hip and groin. If the suspected diagnosis is that of an inguinal hernia, the first-line imaging examination is ultrasonography.

MRI and CT are second-line investigations.

MRI or MR arthrography should be used for assessment of FAIS and acetabular dysplasia including femoral torsion (adding axial images through the distal femur) and for assessing poor prognostic factors for hip preservation surgery (e.g., joint space narrowing, femoral or

acetabular cysts, and bone oedema). MRI should also be used for assessing pubic-, iliopsoas- and adductor-related groin pain.

CT should be used with caution due to the ionizing radiation. However, low dose protocols are widely available and allow for 3D imaging of the hip which is useful for assessment and planning surgical resection in FAIS.

For adductor, inguinal or iliopsoas related groin pain ultrasonography can be utilized.

Finally, a diagnostic hip injection with local anesthetic under imaging guidance form a second line investigation. Pain relief obtained from a local I/A hip injection can reliably differentiate intraarticular from extra-articular pathology.

Grade of Recommendation: C

Agreement: median 9 (6-9)